Multiple Sclerosis and Related Disorders 45 (2020) 102428

Contents lists available at ScienceDirect

Multiple Sclerosis and Related Disorders

journal homepage: www.elsevier.com/locate/msard

Review article

Latin American consensus recommendations for management and treatment of neuromyelitis optica spectrum disorders in clinical practice

Edgar Carnero Contentti[a,*], Juan Ignacio Rojas[b,c], Edgardo Cristiano[b], Vanessa Daccach Marques[d], José Flores-Rivera[e], Marco Lana-Peixoto[f], Carlos Navas[g], Regina Papais-Alvarenga[h], Douglas K. Sato[i], Ibis Soto de Castillo[j], Jorge Correale[k,**]

[a] Neuroimmunology Unit, Department of Neuroscience, Hospital Alemán, Buenos Aires, Argentina
[b] Centro de Esclerosis Múltiple de Buenos Aires (CEMBA), Buenos Aires, Argentina
[c] Neurology Service, Hospital Universitario de CEMIC, Buenos Aires, Argentina
[d] Department of Neurosciences and Behavioral Sciences, Hospital das Clínicas, Ribeirão Preto Medical School, University of São Paulo, São Paulo, Brazil
[e] National Institute of Neurology and Neurosurgery, ABC Medical Center, Mexico City, Mexico
[f] Department of Neurology, Federal University of Minas Gerais Medical School, Belo Horizonte, Brazil
[g] Clinica Enfermedad Desmielinizante, Clinica Universitaria Colombia, Colombia
[h] Hospital da Lagoa, University of Rio de Janeiro (UNIRIO), Rio de Janeiro, Brazil
[i] Brain Institute of Rio Grande do Sul, Pontifical Catholic University of Rio Grande do Sul (PUCRS), Porto Alegre, Brazil
[j] Neurology Department, Hospital Universitario de Maracaibo, Maracaibo, Bolivarian Republic of Venezuela
[k] Department of Neurology, Fleni, Buenos Aires, Argentina

ARTICLE INFO

Keywords:
Neuromyelitis optica spectrum disorder
Consensus recommendations
Diagnosis
Antibody testing
Latin America
Clinical practice

ABSTRACT

Background: During the last two decades, neuromyelitis optica spectrum disorder (NMOSD) has undergone important changes, with new diagnostic markers and criteria, better recognition of clinical phenotypes, better disease prognosis and new therapeutic approaches. Consequently, management of NMOSD patients in Latin American (LATAM) has become more complex and challenging in clinical practice. In making these consensus recommendations, the aim was to review how the disease should be managed and treated among LATAM patients, in order to improve long-term outcomes in these populations.

Methods: A panel of LATAM neurologists who are experts in demyelinating diseases and dedicated to management and care of NMOSD patients gathered virtually during 2019 and 2020 to make consensus recommendations on management and treatment of NMOSD patients in LATAM. To achieve this consensus, the RAND/UCLA methodology for reaching formal consensus was used.

Results: The recommendations focused on diagnosis and differential diagnoses, disease prognosis, tailored treatment, identification of suboptimal treatment response and special circumstances management. They were based on published evidence and expert opinions.

Conclusions: The recommendations of these consensus guidelines seek to optimize management and specific treatment of NMOSD patients in LATAM

1. Introduction

During the last 25 years, neuromyelitis optica (NMO) spectrum disorder (NMOSD) has undergone important changes, with new diagnostic criteria, better recognition of clinical phenotypes, identification of anti-aquaporin-4 antibodies (AQP4-ab), better assay methods, and disease prognosis as well as new therapeutic approaches (Wingerchuk et al., 2015; Flanagan, 2019; Lana-Peixoto and Talim, 2019; Flanagan and Weinshenker, 2014; Weinshenker and Wingerchuk, 2017; Sato et al., 2014a, b; Lennon et al., 2005). However, there remain significant unmet needs with its management, in terms of disease diagnosis, wider symptom control and specific treatment (Wingerchuk et al., 2015; Flanagan, 2019; Lana-Peixoto and Talim, 2019; Flanagan and Weinshenker, 2014; Weinshenker and

* Corresponding author at: Neuroimmunology Unit, Department of Neuroscience, Hospital Alemán, Av Pueyrredón 1640, C1118AAT, Buenos Aires, Argentina (E. Carnero Contentti).
** Co-corresponding author at: Department of Neurology, Fleni, Montañeses 2325, C1428AQL, Buenos Aires, Argentina (J. Correale).
E-mail addresses: ecarnerocontentti@hospitalaleman.com, junior.carnero@hotmail.com (E. Carnero Contentti), jcorreale@fleni.org.ar (J. Correale).

https://doi.org/10.1016/j.msard.2020.102428
Received 25 April 2020; Received in revised form 24 July 2020; Accepted 27 July 2020
2211-0348/ © 2020 Elsevier B.V. All rights reserved.

Wingerchuk, 2017; Sato et al., 2014a, b; Lennon et al., 2005).

Latin America (LATAM) is a large region of the American continent that extends from Mexico (32° North latitude) to the Argentinian and Chilean Patagonia in South America (56° South latitude), including the Caribbean Islands (Alvarenga et al., 2017). LATAM inhabitants are a heterogeneous, multiethnic group of individuals. They have diverse variants and genetic proportions among Mestizos, the most representative ethnic population, who themselves are the product of centuries of interracial mixing between Native Americans (or Amerindians), White Caucasian Europeans, and Black Africans (Alvarenga et al., 2017; Papais-Alvarenga et al., 2015). NMO prevalence in LATAM ranged from 0.37/100,000 (Volta Redonda city) to 4.2/100,000 inhabitants (Caribbean Islands) and NMOSD (Alvarenga et al., 2017; Papais-Alvarenga et al., 2015; Hor et al., 2020), which is not a classic demyelinating disease (Kawachi and Lassmann, 2017), represented 11.8% of all inflammatory diseases of the central nervous system (CNS) in a large multicenter study from South America (Alvarenga et al., 2017; Papais-Alvarenga et al., 2015; Hor et al., 2020; Kawachi and Lassmann, 2017; Rivas-Alonso et al., 2018; Rivera et al., 2008; Soto de Castillo et al., 2019). NMOSD has shown to be significantly different to MS as regards gender, ethnicity, morbidity and genetic susceptibility in this region (Kawachi and Lassmann, 2017; Rivas-Alonso et al., 2018; Rivera et al., 2008; Soto de Castillo et al., 2019). Unfortunately, there are no data on access and utilization of NMOSD care services in LATAM, unlike MS (Carnero Contentti et al., 2020).

Consequently, management of NMOSD patients has become more complex and challenging in clinical practice. Local and regional factors need to be considered when recommending how the disease should be managed and treated. Costs involved in diagnosis acquisition, medications, and long-term care of the disease are challenging for a region where developing health systems are not designed or prepared to adopt adequate NMOSD care as part of their budgetary or societal responsibilities. Therefore, in making these consensus recommendations, the aim was to review how NMOSD (particularly AQP4-ab positive patients) should be managed and treated in LATAM in order to improve long-term outcomes in these populations in clinical practice.

2. Methods

A panel of LATAM experts in neurology who are dedicated to diagnosis and care of NMOSD patients gathered virtually during 2019 and 2020 to make consensus recommendations about management and treatment of NMOSD in LATAM. To achieve consensus, the RAND/UCLA methodology for reaching formal consensus was used (Alvarenga et al., 2017; Papais-Alvarenga et al., 2015; Hor et al., 2020). The method for developing practice guidelines through formal consensus is both a consensus method and a guideline method (Bell et al., 2014; Santori et al., 2008; Rand Corporation 2001). As a consensus method, the purpose is to formalize the degree of agreement among experts by identifying and selecting, through iterative ratings with feedback, the proposals on which experts agree and those points on which they disagree or are undecided. The guideline methods are subsequently based on agreement proposals. As a practice guideline method, the purpose is to draft several recommendations that address questions of interest in clinical practice (Hor et al., 2020). This is a rigorous and explicit method based on involvement of user representatives and professionals in the field to which the guidelines relate, and on use of an external peer review phase, transparency, independence of development and management of conflicts of interest.

The first step in the process consisted of inclusion of working group experts. Experts were selected based on their experience in managing patients with NMOSD in different regions of LATAM. The working group was then divided into: a) a steering group, constituted by three professionals, including two chairpersons of the steering group (E.C.C and J.C) and a project manager; and b) a rating group of eight professionals who, in their daily practice, are directly involved in patient care. After the working group had been formed, the procedure consisted of the following phases:

1. **Systematic review and synthesis of the literature:** A systematic search of the literature, without language restrictions, was carried out on MEDLINE and EMBASE for the period 1990-2019. The search terms were “NMOSD”, together with the modifiers “treatment”, “diagnosis”, “personalized”, “care”, “pharmacovigilance”, “response”, “suboptimal”, “biomarkers”, “aquaporin-4 antibodies”, “magnetic resonance imaging (MRI)“, “precision”, “response”, “diagnosis”, “centers” and “guidelines”. Relevant clinical papers were distributed to the working group for review and summarization so that they could respond to the proposals and recommendations for discussion.
2. **Development of proposal list:** A list of proposals developed by the steering group was submitted to the rating group in the form of a questionnaire. At this stage, the proposals complemented or contradicted each other insofar as they considered all opinions expressed by the group members during the work sessions.
3. **Rating**: Initially, the statements on which the members of the rating group agreed were identified. For statements in which there was no agreement, two more rounds of votes were conducted, with interim feedback sessions based on the published evidence (see supplementary data 1). This phase concluded with selection of the proposals on which there was a consensus within the rating group. Existence of a consensus was defined as a situation in which 70% of the respondents agreed, and lack of consensus, in which ≥ 30% disagreed. The rules for rating and analysis of the scores were defined at the outset and were communicated to the rating group, prior to the first round. At every stage of the rating phase, members of the rating group were able to comment about their response to each statement. All the comments made were also analyzed in a qualitative manner to include comments in the next rating phase.
4. **Drafting the initial version of the guideline:** The steering group and the project manager drafted the first version of the consensus that was to be submitted to the peer review group based on the consensus proposals.
5. **Peer review:** An analytical report was drafted, drawing together all scores and comments from the peer review group members and, where applicable, from the participants in the public consultation.
6. **Finalization:** The final version of the evidence reports, the consensus recommendations and a summary of the guideline were drawn up. The validated versions of these documents were disseminated.

2.1. Recommendations regarding disease diagnosis and immunological tests

-To achieve a confident diagnosis of NMOSD, there must be clinical involvement in at least one of the six CNS regions: optic nerve, spinal cord, area postrema of the dorsal medulla, brainstem, diencephalon or cerebrum.

Previously, involvement of both the optic nerve and spinal cord was mandatory in order to make the diagnosis of NMO in accordance with the 2006 NMO diagnostic criteria, in the absence of brain symptoms (Wingerchuk et al., 2007, 2006). The 2015 International Panel for NMOSD diagnostic criteria (IPND) (Wingerchuk et al., 2015) added area postrema (APS), brainstem (BSS), acute diencephalic syndrome (ADS) and symptomatic cerebral syndrome (SCS), to optic neuritis (ON) and acute transverse myelitis (ATM). This established the spectrum and validity of the clinical syndromes that are reported in clinically diagnosed NMO, thereby defining new core clinical criteria (Wingerchuk et al., 2015). More precise definition of the clinical presentations of NMOSD allow it to be diagnosed in the presence of at least one of the six core clinical characteristics, along with detection of AQP4-ab and ruling out alternative diagnoses (Wingerchuk et al.,

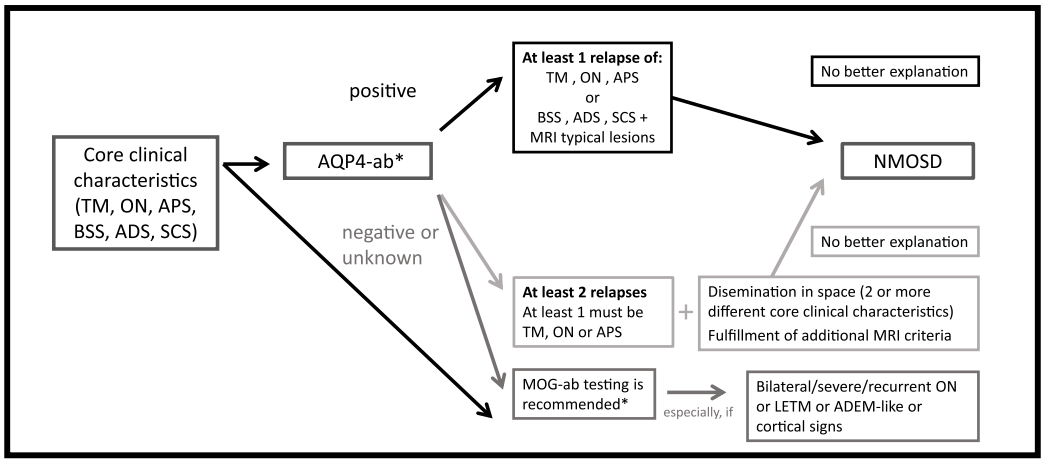

Fig. 1. This schematic diagram illustrates different NMOSD phenotypes according to the 2015 diagnostic criteria for NMOSD and the 2018 MOG international experts consensus recommendations.
Abbreviations: AQP4-ab: anti-aquaporin-4 antibodies, TM: transverse myelitis, ON: optic neuritis, APS: area postrema syndrome, BSS: brainstem syndrome, ADS: acute diencephalic syndrome, SCS: symptomatic cerebral syndrome, MOG-ab: anti-myelin oligodendrocyte glycoprotein antibodies, LETM: longuitudinally extensive transverse myelitis, ADEM: Acute disseminated encephalomyelitis, NMOSD: neuromyelitis optica spectrum disorders. * Given that positivity for both AQP4-ab and MOG-ab is extremely rare using recommended assays, if core clinical characteristics or ADEM-like and/or cortical signs are observed both antibodies should ideally be tested (if available).

2015). In patients who are negative for AQP4-ab or whose status is unknown, the IPND criteria are more stringent and MRI criteria must also be fulfilled.

-The 2015 International Panel for NMOSD diagnostic criteria should be applied to LATAM patients who are suspected of having NMOSD, in order to make diagnosis

In the 2015 IPND criteria (Wingerchuk et al., 2015), revisions of the previous 2006 criteria were recommended (Wingerchuk et al., 2006) (Figure 1). These new criteria defined a uniform concept combining NMO and NMOSD, and consequently the term NMO was retained by using NMOSD (Wingerchuk et al., 2015). The panel emphasized the serological status (including negative and unknown status), the clinical implications of AQP4-ab and presence of highly suggestive MRI lesions. These factors reflect wider NMOSD phenotypes, thus facilitating earlier and more accurate NMOSD diagnosis (Wingerchuk et al., 2015).

Although the 2015 IPND criteria have not been validated in LATAM, it was demonstrated that they increase the rate and speed of NMSOD diagnosis in comparison with the 2006 NMO criteria, in two LATAM cohorts (Carnero Contentti et al., 2018; Fragoso et al., 2019). This result is in line with other reports worldwide (Hamid et al., 2017; Hyun et al., 2016).

-In the LATAM population, in addition to multiple sclerosis (MS), ruling out other regional diseases (local infections and nutritional diseases) that could mimic NMOSD is recommended.

To rule out other regional diseases that mimic NMOSD, careful and detailed medical and epidemiological history-taking and physical examination are crucial (Thompson et al., 2018; Kim et al., 2017; Fragoso et al., 2017; Zatjirua et al., 2011; Delgado-García et al., 2019; Gray et al., 2011; Li et al., 2017; Lana-Peixoto et al., 2018; von Glehn et al., 2012; Cristiano et al., 2020). As shown in Table 1, in LATAM populations, certain infectious and nutritional diseases have higher prevalence, thus mimicking NMOSD, both clinically and on MRI (Thompson et al., 2018; Kim et al., 2017; Fragoso et al., 2017; Zatjirua et al., 2011; Delgado-García et al., 2019; Gray et al., 2011;

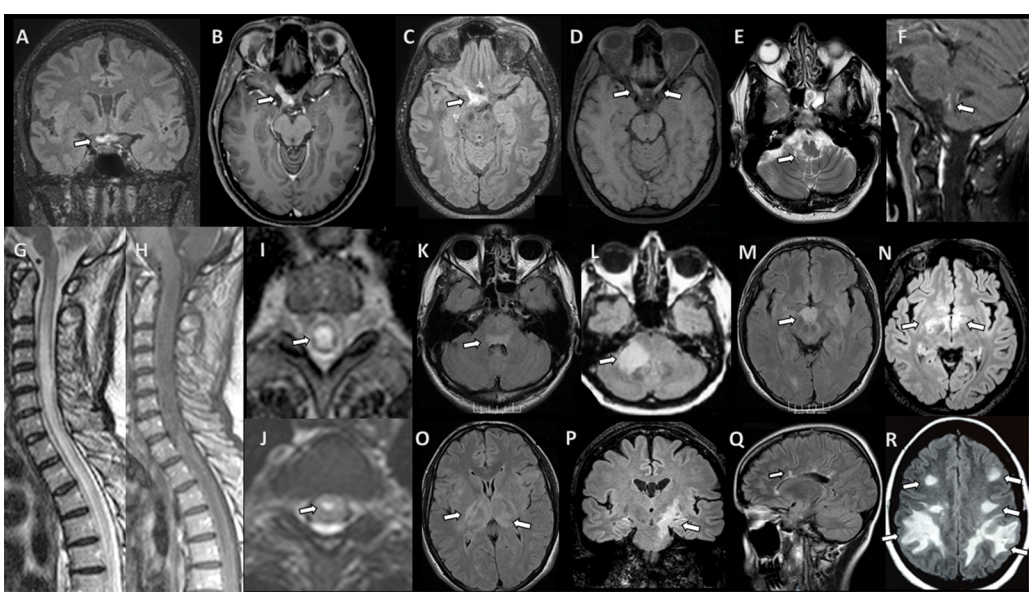

Fig. 2. Characteristic brain and spinal cord abnormalities in AQP4-ab-positive NMOSD patients.
A) Coronal fluid-attenuated inversion recovery (FLAIR) MRI shows an optic chiasm lesion, B) Axial T1-weighted MRI with gadolinium shows right optic nerve lesion, C) Axial FLAIR MRI shows an optic chiasm lesion and right optic nerve lesion D) Axial T1-weighted MRI shows bilateral optic nerve (posterior portion) lesions, E) Axial T2-weighted MRI shows right dorsal medulla lesion (area postrema), F) Sagittal T1-weighted MRI with gadolinium shows dorsal medulla lesion, G) Sagittal T2-weighted MRI shows a lesion hyperintense longitudinally extensive, H) Sagittal T1-weighted MRI shows a lesion hypointense longitudinally extensive, I) Axial T2-weighted MRI shows centrally located with more than half of the cross-sectional cord area lesion, J) Axial T2-weighted MRI shows bright spotty lesion, K) Axial FLAIR MRI shows brainstem lesion adjacent to the fourth ventricle, L) Axial FLAIR MRI shows right brainstem/cerebellum lesion. M) Axial FLAIR MRI shows anterior border of the midbrain N) Axial FLAIR MRI shows periependymal lesions surrounding the third (diencephalic lesion) and cerebral aqueduct lesion, O) Axial FLAIR MRI shows bilateral thalamic lesions and corticospinal tract lesions involving the posterior limb of the internal capsule and cerebral peduncle of the midbrain, P) Coronal FLAIR MRI shows left corticospinal tract lesion, Q) Sagittal FLAIR MRI shows callosal lesions that were compatible with Dawson's fingers, R) Axial T2-weighted MRI shows extensive and tumefactive subcortical hemispheric white matter lesions (some of these confluent lesions look like “spilled ink” along the white matter tracts).

Table 1
Local infections and nutritional diseases as differential diagnosis of NMOSD in LATAM.

General aspect	Causes	Clinical features to diagnosis	Investigations
Infectious diseases	Neurotuberculosis	• Most common manifestation is tuberculous meningitis • Tuberculomas, cerebral miliary tuberculosis, tuberculous encephalopathy and tuberculous abscess may mimic NMOSD at least at the onset of infection	Mantoux tuberculin skin test Interferon gamma release assays, if available Chest X-ray or Chest CT
	Neurosyphilis	• Although optic neuritis and transverse myelitis due to syphilis is rare, it could mimic to NMOSD. • Screening for neurosyphilis is relevant in bilateral optic neuritis and LETM patients because is treatable	VDRL To confirm with FTA-ABS test
	Neurocysticercosis	• Most common presentation is related to epilepsy • MRI could mimic "open-ring" Gd enhancement and NMOSD lesions • Calcified lesions in imaging examinations can aid in the differential diagnosis of MS and NMOSD	Neuroimaging Immunological CSF and serum tests
	Schistosomiasis	• Signs and symptoms of increased intracranial pressure, ataxia, delirium, seizures, visual impairment • Transverse myelitis, including acute transverse myelitis or subacute myeloradiculopathy of the lumbosacral region is the most commonly reported neurological manifestation of both S. mansoni and S. haematobium infection	Stool or urine samples Serological test
	Dengue-virus infection	• Recently become important in the diagnostic workup for brain and spinal demyelination on LATAM populations • Main neurological presentation is encephalopathy/encephalitis • Although transverse myelitis/LETM, cerebellar syndrome and ADEM due to dengue is rare, it could mimic to NMOSD. • Dengue-related MRI findings may be similar to demyelinating diseases	Antibodies for dengue in blood and CSF samples
	Human T-cell lymphotropic virus type 1 (HTLV1)	• Main presentation is progressive spastic paraparesis • Spinal cord clinical picture usually reflects impairment of the dorsolateral columns, which can also be identified by MRI as long-segment hyperintensity on T2 of the lateral columns	Blood or CSF immunological tests
Nutritional deficits	Vitamin B12 deficiency	• Subacute combined degeneration of the spinal cord may manifest as associations of progressive motor, sensitive and autonomic disfunction (erectile impotence, urine and fecal incontinence), gait, ataxia, mental disturbances and optical impairment • Spinal cord MRI shows symmetric bilateral hyperintensity within the dorsal columns (the inverted "V" sign) • Dietary deficiency (vegan/vegetarian diet or excessive alcohol intake), malabsorption (history of surgery, drugs, infections), pernicious anemia.	Vitamin B12 levels Complete blood count Others: Homocysteine leves Antibodies against Anti-Intrinsic factor antibody Methylmalonic acid levels
	Folate deficiency	• Chronic and slowly progressive myelopathy, with gait impairment because of sensory ataxia • Spinal cord MRI findings are similar to patients with vitamin B12 deficiency • Dietary, malabsorption and bariatric surgery	Folate levels Complete blood count
	Copper deficiency	• Chronic and slowly progressive myelopathy, with gait impairment because of sensory ataxia and lower limb spasticity • Spinal cord MRI findings are similar to patients with vitamin B12 deficiency • History of zinc supplementation, gastric band surgery or malabsorption syndrome.	Copper serum levels Zinc serum levels Complete blood count 24-hour urine test for copper
Demyelinating disease	Multiple sclerosis	• Unilateral optic neuritis, partial transverse myelitis, brainstem/cerebellar syndrome and cerebral syndrome • Ovoid/round lesions adjacent to a lateral ventricle, inferior temporal lobe lesion, U fibers lesions, Dawson's finger-type lesions and partial spinal cord lesions can distinguish MS from distinct aquaporin-4 antibodies serostatus NMOSD	Brain and spinal MRI CSF proteins and white blood cells OCB OCT and VEPs

NMOSD: neuromyelitis optica spectrum disorders, CT: computed tomography, VDRL: venereal disease research laboratory, FTA-ABS: fluorescent treponemal antibody absorption, LETM: longitudinally extensive transverse myelitis, CSF: cerebrospinal fluid, MRI: magnetic resonance imaging, MS: multiple sclerosis, Gd: gadolinium, ADEM: Acute disseminated encephalomyelitis, OCT: Optical coherence tomography, VEPs: visual evoked potentials.

Li et al., 2017; Lana-Peixoto et al., 2018; von Glehn et al., 2012; Cristiano et al., 2020).

-Patients with suspected NMOSD should be evaluated in a center with experience in diagnosing of demyelinating diseases, to ensure an earlier and more precise diagnosis and adequate treatment.

A referral to a neurologist with experience in NMOSD offers the opportunity to ensure that the diagnosis of NMOSD is correct. In a retrospective multicenter study in Europe, it was reported that 42.5% of NMO patients were misdiagnosed as having MS, mostly before AQP4-ab testing had become available (Jarius et al., 2012). Misdiagnosis may have a significant impact on NMOSD care and on the costs to the healthcare system in our region. Accumulated disability as a result of failure to provide swift treatment for relapses may result in long-term neurological sequelae and delays in diagnosing NMOSD. In addition, there needs to be improved patient referral and understanding the impact of the relapses, as well as highly suggestive MRI lesions, together with an integrated multidisciplinary team approach towards limiting patient disability (Wingerchuk et al., 2015; Flanagan, 2019; Lana-Peixoto and Talim, 2019; Flanagan and Weinshenker, 2014; Weinshenker and Wingerchuk, 2017). An integrated approach to

clinical, laboratory and imaging examinations will enable accurate and precise differential diagnoses in suspected NMOSD patients (Wingerchuk et al., 2015; Flanagan, 2019; Lana-Peixoto and Talim, 2019; Flanagan and Weinshenker, 2014; Weinshenker and Wingerchuk, 2017; Mutch et al., 2014). Optical coherence tomography (OCT) can be a useful additional emerging tool in differentiating NMOSD from MS. Thus, OCT has shown that thinning of both peripapillary retinal nerve fiber layer and ganglion cell/inner plexiform layer after an ON relapse is more severe in AQP4-ab-positive NMOSD and MOG-ab-associated disease than in MS, in line with the clinical experience of poor vision outcomes in NMOSD (Bennett et al., 2015; Sotirchos et al., 2019; Oertel et al., 2017).

2.2. AQP4-ab, anti-myelin oligodendrocyte glycoprotein antibodies (MOG-ab) and lumbar puncture (PL) test statements

-Patients with suspected NMOSD should be tested for serum AQP4-ab.

Identification of the autoantibody biomarker AQP4-ab in 2004 was an important milestone in differentiating NMO from MS (Lennon et al., 2005, 2004). Although the presence of AQP4-ab alone is not an absolute criterion for diagnosing NMOSD, it is frequently found (about 80%), in patients who fulfill the 2015 NMOSD criteria, when detected using an appropriate test, as reported in different large cohorts worldwide (Wingerchuk et al., 2015; Lennon et al., 2005, 2004; Prain et al., 2019; McCreary et al., 2018; Waters et al., 2012). Thus, detection of AQP4-ab is specific for confirming the NMOSD diagnosis in an appropriate clinical context (Wingerchuk et al., 2015). Nevertheless, analysis of AQP4-ab may not be widely available in LATAM using adequate laboratory techniques. It is also worth mentioning that the test results can be affected by a number of analytical, disease and treatment-related factors (Wingerchuk et al., 2015; Flanagan, 2019; Lana-Peixoto and Talim, 2019; Flanagan and Weinshenker, 2014; Weinshenker and Wingerchuk, 2017; Jarius and Wildemann, 2013; Takahashi et al., 2007; Fujihara and Sato, 2013; Marignier et al., 2013). Thus, up to 20-30% of NMOSD patients, depending on the assay used, can be negative for AQP4-ab (Wingerchuk et al., 2015; Flanagan, 2019; Lana-Peixoto and Talim, 2019; Flanagan and Weinshenker, 2014; Weinshenker and Wingerchuk, 2017); been these results higher in LATAM population (up to 35%; probably due to the methodology used (Carnero Contentti et al., 2020))

-Serum AQP4-ab is best tested using cell-based assay (CBA) methods, whenever feasible, because of greater sensitivity and specificity.

Assay techniques for analyzing AQP4-ab status differ in their sensitivity and specificity (Waters et al., 2012; Fryer et al., 2014). In general, all AQP4-ab assays have been shown to be highly specific (97-100%) (Lennon et al., 2004; Prain et al., 2019; McCreary et al., 2018; Waters et al., 2012; Fryer et al., 2014). Direct fluorescence CBAs and fluorescence-activated cell sorting (FACS) assays have been shown to be the most sensitive and specific techniques for detecting serum AQP4-ab (Lennon et al., 2004; Prain et al., 2019; McCreary et al., 2018; Waters et al., 2012; Fryer et al., 2014). The sensitivity of CBAs was recently reported as being higher (92%) than those of the enzyme-linked immunosorbent assay (ELISA; 60%) and tissue-based indirect immunofluorescence (IIF; 78%) among NMOSD patients in Australia and New Zealand who fulfilled the 2015 IPND diagnostic criteria (Prain et al., 2019). Serum was identified as being more sensitive than cerebrospinal fluid (CSF) for detecting AQP4-ab using FACS and commercial CBA methods (Majed et al., 2016). Therefore, serum is the most practical and cost-effective material for AQP4-ab testing.

-If CBA is not available, the ELISA technique is acceptable. However, patients without a typical clinical presentation of NMOSD should undergo a follow-up CBA: positive results would confirm NMOSD if ELISA is positive

CBA is strongly recommended, according to the 2015 IPND (a list of the referral centers where the authors work, performing AQP4-ab and MOG-ab detection through LATAM is showed in supplementary date 2) (Wingerchuk et al., 2015). ELISA may easily quantify the titer of AQP4-ab but has relatively low accuracy and has been shown to have higher false-positive rates in different studies conducted in Europe and Oceania, particularly among MS patients (Prain et al., 2019; McCreary et al., 2018; Waters et al., 2012; Jarius and Wildemann, 2013; Kim et al., 2012), when the titers are low. In addition, differential diagnoses are needed particularly if non-typical NMOSD clinical presentation or MRI lesions are found (Kim et al., 2017).

-To analyze AQP4-ab, serum samples should be taken before administering high-dose intravenous methylprednisolone (IVMP) or starting plasmapheresis (PLEX). However, treatment should not be deferred until the results are available.

Different clinical and serological conditions may lower the accuracy of AQP4-ab testing (Wingerchuk et al., 2015; Flanagan, 2019; Lana-Peixoto and Talim, 2019; Flanagan and Weinshenker, 2014; Weinshenker and Wingerchuk, 2017; Jarius and Wildemann, 2013; Takahashi et al., 2007; Fujihara and Sato, 2013; Marignier et al., 2013). Likewise, it has been reported that serum AQP4-ab titers became lower after IVMP and PLEX treatment (Takahashi et al., 2007). Therefore, AQP4-ab samples should preferably be obtained during a relapse or before immunotherapy (Takahashi et al., 2007; Nishimura et al., 2018 Sep). However, patients with suspected NMOSD should not be given different treatment until the AQP4-ab result has been obtained, since relapses are usually severe and often lead to permanent disability if not treated promptly. Serum samples can be obtained and sent for analysis, and treatment can be started, while awaiting AQP4-ab results.

-AQP4-ab should be repeated after 3-6 months if the initial results were negative and suspicion of NMOSD is high (based on clinical and MRI features).

From expert opinions and reviews of the literature, negative findings from initial AQP4-ab testing lead to increased sensitivity of AQP4-ab detection in repeat testing 3–6 months later, especially if the initial test was performed during clinical remission, under immunosuppressant treatment (IST) or immediately following PLEX (Kim et al., 2017; Waters et al., 2012, 2014; Jarius et al., 2008; Palace et al., 2012; Trebst et al., 2014; Whittam et al., 2017). Information from a few studies suggests that a slow increase in serum AQP4-ab titers occurs over time, even before a clinical relapse (Nagaishi et al., 2011). Special attention should be given to repeat AQP4-ab testing among seronegative patients with typical NMOSD manifestations, especially those with APS, neuropathic pain (Hyun et al., 2020; Asseyer et al., 2018) and paroxysmal painful tonic spasm (Carnero Contentti et al., 2016; Liu et al., 2017). These have been reported to occur more frequently in NMOSD than in MS and have a high impact on quality of life (Trebst et al., 2014; Whittam et al., 2017; Beekman et al., 2019). Retesting AQP4-ab is especially recommended during a relapse and/or during treatment-free intervals, possibly 3–6 months after a previous examination and particularly with a more sensitive assay (Waters et al., 2014; Trebst et al., 2014; Whittam et al., 2017).

-Clinical attacks of ON, ATM or APS in patients with systemic autoimmune disease (e.g. systemic lupus erythematosus [SLE] or Sjögren's syndrome [SS]) should be tested for AQP4-ab.

NMOSD is frequently associated with other systemic autoimmune diseases, particularly SS and SLE (Wingerchuk et al., 2007; Pittock et al., 2008; Birnbaum et al., 2017; Wingerchuk and Weinshenker, 2012). While antinuclear autoantibodies are often found in NMOSD patients (even in those who do not have clinical evidence of a systemic autoimmune disease), positivity for AQP4-ab in patients with systemic autoimmune diseases associated with cardinal manifestations of NMOSD such as ATM, ON or APS lead to the diagnosis of NMOSD (Wingerchuk et al., 2007; Pittock et al., 2008; Birnbaum et al., 2017; Wingerchuk and Weinshenker, 2012). Patients with SLE and SS

but without symptoms of CNS involvement are consistently negative for AQP4-ab (Pittock et al., 2008; Birnbaum et al., 2017), which suggests that NMOSD is a separate entity from systemic rheumatic CNS diseases and that it may be attributable to a particular susceptibility for autoimmune diseases in those patients (Wingerchuk et al., 2007; Pittock et al., 2008; Birnbaum et al., 2017; Wingerchuk and Weinshenker, 2012).

-In patients with clinically suspected NMOSD with non-typical brain or spinal cord MRI lesions* suggestive of *MS, lumbar puncture with investigation of white blood cell count, protein levels, and oligoclonal bands (OCB) in CSF and serum is recommended, to evaluate differential diagnoses.

To avoid NMOSD misdiagnosis, evaluation of regional and non-regional differential diagnoses is crucial, as previously mentioned above. In this regard, CSF abnormalities are frequent during a NMOSD relapse and disappear during remission, but their role is still limited (Kim et al., 2017; Trebst et al., 2014). Mixed pleocytosis (lymphocytes, monocytes, polymorphonuclear and eosinophils cells), which might be elevated (up to 1000/mm^3), and high protein levels are commonly found (Kim et al., 2011; Sellner et al., 2010; Ghezzi et al., 2004; Wingerchuk et al., 1999; Jarius et al., 2011). In contrast, CSF white blood counts higher than 50 cells/mm^3 and protein content more than 100 mg/dl are very rare in MS patients, but are found in up to 35% of NMOSD patients (Kim et al., 2011, Sellner et al., 2010, Ghezzi et al., 2004, Wingerchuk et al., 1999, Jarius et al., 2011).

-The presence of OCB in CSF does not rule out the diagnosis of NMOSD

While OCB in CSF occurs in 90% of Caucasian MS patients (Thompson et al., 2018), this is typically absent in NMOSD. However, OCB has been reported in up to 25-43% of NMOSD patients (17.1% in a LATAM cohort) (Carnero Contentti et al., 2020), particularly during a relapse. It can be transitory and mostly disappears in follow-up samples (Wingerchuk et al., 2007; Kim et al., 2017; Trebst et al., 2014; Whittam et al., 2017; Nagaishi et al., 2011; Hyun et al., 2020; Asseyer et al., 2018; Carnero Contentti et al., 2016; Liu et al., 2017; Beekman et al., 2019; Pittock et al., 2008; Birnbaum et al., 2017; Wingerchuk and Weinshenker, 2012; Kim et al., 2011; Sellner et al., 2010; Ghezzi et al., 2004; Wingerchuk et al., 1999; Jarius et al., 2011, 2010; Bergamaschi et al., 2004). Therefore, the presence of OCB does not rule out a diagnosis of NMOSD.

It is important to note that there are no reliable values on the real percentage of MS and NMOSD patients with OCBs in LATAM.

-In patients with suspicion of NMOSD who were negative for AQP4-ab (tested via CBA), performing MOG-ab is recommended.

-CBA must be used as the gold standard for evaluating MOG-ab in serum.

-The 2018 expert recommendations for MOG-ab-associated disease (Jarius et al., 2018) ***should be applied to LATAM patients who are suspected of having MOG-ab-associated disease, in order to make the diagnosis.***

The role of MOG-ab in inflammatory CNS diseases has been reviewed (Sato et al., 2014a, b). Although these antibodies were associated with MS, their presence could not be reproduced in subsequent studies (Reindl and Waters, 2019). MOG-ab was found to be present in the serum of up to 40% of AQP4-ab-negative NMOSD patients (Jarius et al., 2016; Hamid et al., 2017), while in Brazil, these values were significantly lower (5/68; 7%) (Papais-Alvarenga et al., 2018). The presence of MOG-ab may discriminate between AQP4-ab-negative NMOSD patients and MS patients (Jarius et al., 2018, 2016; Reindl and Waters, 2019; Hamid et al., 2017; Papais-Alvarenga et al., 2018; Juryńczyk et al., 2019). Positivity for both AQP4-ab and MOG-ab is extremely rare when both assays are used (Juryńczyk et al., 2019). Indeed, several studies have clearly shown that MOG-ab-associated disease is a distinct entity from classical NMOSD, including two Brazilian cohorts (Sato et al., 2014; Jarius et al., 2016, 2018; Reindl and Waters, 2019; Hamid et al., 2017; Papais-Alvarenga et al., 2018; Juryńczyk et al., 2019; Waters et al., 2015; Reindl et al., 2020; Zamvil and Slavin, 2015; Narayan et al., 2018).

The panel recommends that MOG-ab-associated disease should be diagnosed in patients with any clinical feature suggestive of NMOSD who are negative for AQP4-ab, particularly in cases of ON, ATM, brainstem encephalitis, encephalitis or any combination of these syndromes (Jarius et al., 2018; Reindl and Waters, 2019; Jarius et al., 2016; Hamid et al., 2017; Papais-Alvarenga et al., 2018; Juryńczyk et al., 2019). However, it must be taken into account that an indiscriminate MOG-ab testing will probably elevate the false-positive rate (Juryńczyk et al., 2019). In this regard, it is also critical to use an adequate measurement technique (Papais-Alvarenga et al., 2018; Juryńczyk et al., 2019).

A CBA using cells transfected with full-length human MOG, can detect specific autoantibodies, which recognize conformational epitopes of MOG has the highest sensitivity and specificity (Jarius et al., 2018; Juryńczyk et al., 2019; Waters et al., 2015; Reindl et al., 2020, Zamvil and Slavin, 2015), as well as high reproducibility between different referral centers (Flanagan, 2019). Therefore, CBA using immunofluorescence or flow cytometry is currently recommended as the gold standard to measure MOG-ab (Jarius et al., 2018; Juryńczyk et al., 2019; Waters et al., 2015; Reindl et al., 2020; Zamvil and Slavin, 2015).

2.3. Recommendations for MRI and complementary tests at diagnosis and follow-up

-To diagnose NMOSD, a standardized MRI protocol should be applied at diagnosis and follow-up.

Brain and spinal MRI have important roles in making differential diagnoses and are very important tools for identifying patients with NMOSD (Kim et al., 2015; Carnero Contentti et al., 2018). Most lesions observed on MRI in NMOSD patients are not typical for MS, and only 10%-20% of patients who have brain lesions will meet the Barkhof criteria for MS (Kim et al., 2015). Brain MRI findings can differentiate MS from different AQP4-ab serostatus NMOSD using T2-weighted and FLAIR sequences, including LATAM patients (Table 2) (Matthews et al., 2013; Carnero Contentti et al., 2019). These MRI features suggestive of MS were included in the 2015 IPND criteria for NMOSD as “red flags“ (Wingerchuk et al., 2015). Another study from LATAM has shown significant differences in lesion distribution at disease onset as well as in brain volumes during follow-up between NMOSD and MS (Silveira et al., 2020). Adequate repositioning (manually or via an automated positioning system) is needed to allow consistent comparisons among follow-up scans.

Because MS and other local diseases may at disease onset mimic NMOSD, standardization of MRI protocols for demyelinating diseases across LATAM centers is very important, since this would enable uniform performance and correct interpretation of studies. The recommended brain protocol is shown in Table 2.

-At NMOSD diagnosis, spinal cord MRI is recommended, following a standardized imaging protocol.

NMOSD patients can present ATM at disease onset or during follow-up. Around 85% of acute lesions extend ≥ 3 spinal segments (LETM) (Ciccarelli et al., 2019), which helps to differentiate AQP4-ab-positive NMOSD from MS and to facilitate the differential diagnosis (Kim et al., 2015; Carnero Contentti et al., 2018, 2019; Matthews et al., 2013; Silveira et al., 2020; Ciccarelli et al., 2019). Use of an MRI scanner with a minimum field strength of 1.5-T is strongly recommended (Ciccarelli et al., 2019). The recommended spinal cord protocol is shown in Table 2.

-In patients with short-segment myelitis (STM) on MRI (lesions affecting < 3 segments on sagittal spinal cord MRI) and normal or non-typical brain lesions for MS, APQ4-ab testing should be performed.

While STM was observed in 8% of NMOSD patients in LATAM (Carnero Contentti et al., 2018), it has been reported in up to 19.8% of

Table 2
Standardized protocol for brain and spinal cord MRI across LATAM and MRI NMOSD-typical lesions.

Brain and orbital MRI protocol	Brain MRI NMOSD-typical lesions (clinical application)
Brain MRI protocol	Brainstem/cerebellum (periependymal surfaces of the fourth ventricle and cerebellar peduncle)
Axial proton-density and/or T2-FLAIR/T2-weighted	Area postrema (dorsal medulla or contiguous with an upper cervical spinal cord lesion)
Sagittal 2D or 3D T2-FLAIR	Diencephalic lesions (hypothalamus/thalamus) or periependymal surfaces of the third ventricle
2D or 3D pre and post contrast-enhanced T1-weighted	Optic nerve (lesion extending over 50% optic nerve length or involving optic chiasm)
T1 3D high resolution isotropic sequence at least 10 min after injection of contrast	Periependymal lesions surrounding the lateral ventricles (at least 50% of the length of the corpus callosum)
Orbital MRI protocol	Corticospinal tract lesions
Coronal T2-weighted, FLAIR and STIR	Hemispheric white matter lesions (> 3 cm in longest diameter)
Axial T2-weighted, FLAIR, STIR	"Cloud-like" enhancing lesions
Pre- and post-Gd on T1	
Spinal cord MRI protocol	**Spinal MRI NMOSD-typical lesions (clinical application)**
Sagittal dual-echo (proton-density and T2-weighted) conventional and/or fast spin-echo	Hyperintensity on sagittal T2-weighted (standard T2-weighted, proton density, or STIR sequences) extending over 3 or more vertebral segments
Sagittal STIR (as an alternative to proton-density-weighted)	Central cord (more than 70% of the lesion residing within the central gray matter) cross-sectional involvement
Sagittal contrast-enhanced T1-weighted spin-echo (if T2 lesions present)	T1-weighted gadolinium enhancement lesions (no specific distribution or pattern of enhancement is required)
Axial 2D and/or 3D T2-weighted fast spin-echo Axial contrast-enhanced T1-weighted spin-echo	Rostral extension of the lesion into the brainstem
	Spinal cord swelling.
	Hypointensity on T1-weighted sequences corresponding to region of hyperintensity on T2-weighted (common on acute lesions)
	Bright spotty lesions

NMOSD patients worldwide (Jarius et al., 2012; Flanagan et al., 2015; Hu et al., 2018; Huh et al., 2017). The length of the lesion depends on the timing of the MRI scan (Carnero Contentti et al., 2018; Flanagan et al., 2015). Additionally, no significant differences in distribution lesion frequencies on axial topography (central vs. peripheral) were described in NMOSD patients who experienced STM (Jarius et al., 2012; Carnero Contentti et al., 2018; Flanagan et al., 2015; Hu et al., 2018). Although STM is rare in NMOSD, it should be considered as an initial manifestation to avoid NMOSD misdiagnosis or delay in making the NMOSD diagnosis and implementing specific treatment. Thus, AQP4-ab should be performed if MS has not been diagnosed (Flanagan et al., 2015).

-In patients with STM on MRI and normal or non-typical brain lesions for MS, who are negative for APQ4-ab, MOG-ab testing should be performed.

STM has been reported at least once over the course of the disease in around 44%–52% of all MOG-disease patients (Jarius et al., 2018, 2016; Reindl and Waters, 2019; Hamid et al., 2017; Papais-Alvarenga et al., 2018; Juryńczyk et al., 2019; Mariotto et al., 2017). Therefore, in patients who do not fulfill the 2017 diagnostic criteria for MS (Thompson et al., 2018) or who are negative for AQP4-ab, MOG-ab should be performed in order to allow a specific diagnosis (Jarius et al., 2018).

-In patients with ON, orbital MRI following a standardized protocol is recommended in order to facilitate differential diagnosis and to assess typical NMOSD lesions.

At disease onset, ON has a broad range of differential diagnoses (Amaral et al., 2020; Carnero Contentti et al., 2019; Petzold et al., 2014). Although orbital MRI is not required for the ON diagnosis, both orbital and brain MRI are necessary for evaluating differential diagnoses between different autoimmune and inflammatory optic neuropathies as well as compressive / neoplastic optic nerve affection, and detecting asymptomatic demyelinating lesions. Differentiation is critical for treatment choice and further patient management (Petzold et al., 2014).

Orbital MRI is increasingly being relied on to confirm the ON diagnosis when the clinical diagnosis is uncertain (McKinney et al., 2013; Bursztyn et al., 2019; Srikajon et al., 2018). Orbital MRI in association with fat-suppression techniques has been shown to have higher sensitivity and specificity in detecting lesions suggestive of NMOSD (McKinney et al., 2013). Bilateral optic nerve involvement, posterior nerve predominance (especially with extension into the optic chiasm) or extensive lesions of the optic nerve (more than half of its length) are all suggestive of NMOSD, and they are different from those observed in MS (Wingerchuk et al., 2015; Kim et al., 2015; Carnero Contentti et al., 2018). The recommended orbital protocol is shown in Table 2.

2.4. Recommendations for disease prognosis

-Number of relapses and their severity in NMOSD patients, during the first two years, predicts medium/long-term disability (5 to 10 years).

Phenotypically, a secondary progressive clinical course in NMOSD is uncommon (Wingerchuk et al., 2007) and 90% of NMOSD patients have a relapsing course (Sellner et al., 2010; Ghezzi et al., 2004; Wingerchuk et al., 1999; Jarius et al., 2016). NMOSD patients have reported mean annualized relapse rates (ARR) of 0.82–1.3 (Sellner et al., 2010; Ghezzi et al., 2004; Wingerchuk et al., 1999; Jarius et al., 2016; Kitley and Leite, 2012; Palace et al., 2019) with a median time to reach the first relapse of 10–17 months (Ghezzi et al., 2004; Jarius et al., 2016; Kitley and Leite, 2012; Palace et al., 2019; Papais-Alvarenga et al., 2015). Disability is relapse-related (Kitley and Leite, 2012; Palace et al., 2019), particularly represented by persistent paraplegia and blindness. Long-term outcomes from relapses were strongly correlated with the severity of the relapse at presentation, regardless of treatment timing (Banerjee et al., 2019; Seok et al., 2016) and the initial onset attack (Palace et al., 2019). A history of severe relapse before an initial treatment was an independent risk factor for relapse after adjusting treatments (Palace et al., 2019; Shi et al., 2019). Although it has been reported that the location of the first relapse had no impact on the subsequent disability (Palace et al., 2019), patients with cerebral or brainstem-onset relapses experienced the highest relapse risk (Drulovic et al., 2019). Additionally, ON at disease onset has been reported to be more likely to develop with severe visual disability, compared with other symptoms at onset (Palace et al., 2019).

NMOSD patients have reduced life expectancy, with death often attributable to relapse, especially due to high risk of respiratory failure, extension of cervical lesions into the brainstem or primary brainstem relapses (Sellner et al., 2010; Ghezzi et al., 2004; Wingerchuk et al., 1999; Kitley and Leite, 2012; Palace et al., 2019; Papais-Alvarenga et al., 2015; Banerjee et al., 2019; Seok et al., 2016; Shi et al., 2019; Drulovic et al., 2019; Papais-Alvarenga et al., 2008; Wingerchuk and Weinshenker, 2003). Higher relapse frequency during the first two years of disease was associated with both high risk of

relapses (Palace et al., 2019) and mortality due to NMOSD (Hu et al., 2018). The estimated mortality rate in different series was 15-30% (Kitley and Leite, 2012; Palace et al., 2019; Wingerchuk and Weinshenker, 2003; Mealy et al., 2018). However, recent estimates allowed establishing a lower mortality rate, probably based on an earlier diagnosis. In contrast, older age at disease onset, association with other autoimmune diseases as well as Japanese and African ancestry were associated with a worse prognosis (Carnero Contentti et al., 2020; Kitley and Leite, 2012; Palace et al., 2019; Wingerchuk and Weinshenker, 2003; Mealy et al., 2018).

-At disease onset, the presence of AQP4-ab in NMOSD patients predicts worse medium/long-term disability.

AQP4-ab-positive status predicts a high risk of relapses in untreated patients with an initial event of NMOSD (LETM and ON) over time, even within the first year (Matiello et al., 2008; Weinshenker et al., 2006). Recently, a prospective study reported that AQP4-ab-positive NMOSD patients without IST have a risk of relapse of 94% at five years (Shi et al., 2019). Currently, there is no relationship between antibodies titers and clinical and radiological activity, thus diminishing the likelihood of a specific cut-off that may predict relapses (Jarius and Wildemann, 2013; Waters et al., 2014; Jarius et al., 2008).

2.5. Recommendations for relapse and disease management

-Early IVMP treatment (1 g daily for 3–5 days) in acute relapses is recommended.

Because of the risk of severe residual disability following relapses, therapies for acute relapses are very important and need to be started as early as possible. In AQP4-ab-positive ON patients even a 7-day delay in IVMP initiation was detrimental to vision (Wingerchuk et al., 2015; Flanagan, 2019; Lana-Peixoto and Talim, 2019; Flanagan and Weinshenker, 2014; Weinshenker and Wingerchuk, 2017; Palace et al., 2012; Trebst et al., 2014; Stiebel-Kalish et al., 2019). In addition, evaluation of occult infection or metabolic alterations to diagnose pseudo-relapses should be performed. Although there are no randomized controlled trials on large cohorts regarding treatment of acute relapses, NMOSD patients are typically treated with 1 g of IVMP for 3–5 consecutive days (Flanagan, 2019; Lana-Peixoto and Talim, 2019; Flanagan and Weinshenker, 2014; Weinshenker and Wingerchuk, 2017; Palace et al., 2012; Trebst et al., 2014) and we recommended this management. Complete recovery through use of IVMP has been reported in up to 35% of NMOSD relapses (Abboud et al., 2016; Kleiter et al., 2016). Moreover, after a qualitative analysis, some panel members have also recommended treatment for up to 7 days, as reported recently (Songthammawat et al., 2019).

-After IVMP treatment, a slow tapering course of oral steroids for 2–8 weeks, depending on the severity of the attack, is recommended.

Oral steroids may be started following IVMP treatment, in order to ensure a prolonged effect on inflammation and to avoid an early relapse (or rebound) (Palace et al., 2012; Trebst et al., 2014). Oral prednisone or its equivalent taper starting with 1 mg/kg/day and decreasing gradually over several weeks is recommended. Its administration will depend on the timing of IST start, severity of the attack, patient comorbidities and tolerance of oral steroids (Palace et al., 2012; Trebst et al., 2014). Although there is a lack of controlled trials, oral steroids may be useful as a bridge after a NMOSD diagnosis has been confirmed, until another steroid-sparing therapy reaches full efficacy (Flanagan, 2019; Lana-Peixoto and Talim, 2019; Flanagan and Weinshenker, 2014; Weinshenker and Wingerchuk, 2017; Palace et al., 2012; Trebst et al., 2014).

-PLEX or* immunoadsorption *can be beneficial if there is partial or no response within 5 days from NMOSD relapse onset with or without previously IVMP.

Patients with severe NMOSD relapses and those who do not respond to treatment with IVMP may benefit from 5-7 PLEX procedures (approximately 1.5 plasma volumes every other day) over a two-week period (Flanagan, 2019; Lana-Peixoto and Talim, 2019; Flanagan and Weinshenker, 2014; Weinshenker and Wingerchuk, 2017; Palace et al., 2012; Trebst et al., 2014). Many retrospective studies (Abboud et al., 2016; Kleiter et al., 2016; Songthammawat et al., 2019 ; Bonnan and Cabre, 2012; Bonnan et al., 2018; Kleiter et al., 2018) and a prospective randomized sham-controlled crossover trial (Weinshenker et al., 1999) demonstrated improved outcomes (both clinical and radiological (Magaña et al., 2011)) when NMOSD patients were treated with PLEX as early as possible during a relapse. The likelihood of significant recovery decreased from 50% with PLEX immediately (day 0), to 1% to 5% after day 20, thus emphasizing the importance of early treatment (Bonnan et al., 2018). The time from relapse onset to start of PLEX was a strong predictor of complete remission (Abboud et al., 2016; Kleiter et al., 2016; Songthammawat et al., 2019 ; Bonnan and Cabre, 2012; Bonnan et al., 2018; Kleiter et al., 2018; Weinshenker et al., 1999; Magaña et al., 2011). Additionally, no differences between PLEX and immunoadsorption were found with regard to efficacy for NMOSD relapses (Bonnan et al., 2018; Kleiter et al., 2018). Moreover, 51% of NMOSD patients who were treated with IVMP for 5 days followed by PLEX recovered to pre-relapse baseline status, compared with 16.6% of NMOSD patients treated only with IVMP (Abboud et al., 2016).

These results confirm that starting PLEX early during severe NMOSD relapses provides improved clinical benefit. Neurologists should not perceive PLEX as a rescue therapy only after steroid failure. The therapy should be individualized according to how the relapse is manifested and what the response to previous therapies was (Abboud et al., 2016; Kleiter et al., 2016; Songthammawat et al., 2019 ; Bonnan and Cabre, 2012; Bonnan et al., 2018; Kleiter et al., 2018; Weinshenker et al., 1999; Magaña et al., 2011).

-The clinical benefit of PLEX diminishes after day 20, whether or not IVMP has been administered; therefore, starting PLEX early is recommended.

It has been reported that the maximum improvement is observed when the delay in starting PLEX is minimized ($\leq$ 5 days), such that the clinical benefits gradually diminish, the longer the delay in starting PLEX is (see also the preceding and next statements) (Abboud et al., 2016; Kleiter et al., 2016; Songthammawat et al., 2019 ; Bonnan and Cabre, 2012; Bonnan et al., 2018; Kleiter et al., 2018; Weinshenker et al., 1999; Magaña et al., 2011).

-PLEX should be considered for NMOSD patients with persistent neurological deficits, even beyond day 20 (acute phase) and particularly within 90 days after the attack onset.

As previously mentioned, PLEX has been shown to be beneficial, if it is implemented as early as possible. However, in a Korean study, the response rates did not differ significantly between NMOSD patients treated within 20 days and those treated after 20 days (66.7% and 61.5%, respectively) (Lim et al., 2013). Although it might be appropriate to consider PLEX for NMOSD patients without improvement within 90 days, other clinical or radiological factors relating to ongoing disease activity should help guide in making this decision.

2.6. Recommendations for long-term relapse prevention

The following are recommendations for AQP4-ab-positive NMOSD patients. Treatment strategies for MOG-ab-associated disease and double-negative NMOSD patients, where there are still controversies regarding treatment strategies, were not considered.

-Early start of IST treatments to reduce disease activity and therefore to prevent NMOSD attacks is recommended.

Long-term relapse prevention treatment is recommended for all AQP4-ab-positive and negative patients who are diagnosed with relapsing NMOSD (Flanagan, 2019; Lana-Peixoto and Talim, 2019; Flanagan and Weinshenker, 2014; Weinshenker and Wingerchuk, 2017; Palace et al., 2012; Trebst et al., 2014). In an outcome prediction model among AQP4-ab-positive NMOSD patients, IST treatment significantly

diminished the rates of recurrence, whereas some MS treatment including interferon-β, fingolimod, alemtuzumab and natalizumab increased the risk of relapse (Palace et al., 2019). This emphasizes the importance of differential diagnosis between NMOSD and MS (Wingerchuk et al., 2015; Flanagan, 2019; Lana-Peixoto and Talim, 2019; Flanagan and Weinshenker, 2014; Weinshenker and Wingerchuk, 2017). Azathioprine (AZA), mycophenolate mofetil (MMF) and rituximab (RTX) are the most widely used agents to treat NMOSD (Collongues et al., 2019). Most recently, monoclonal antibodies such as eculizumab, inebilizumab and satralizumab have been shown to reduce the risk of new exacerbations, in comparison with placebo (Pittock et al., 2019; Cree et al., 2019; Yamamura et al., 2019). To date, in clinical practice, the current treatment paradigm is based on retrospective and observational studies, case series and expert opinion (Flanagan, 2019; Lana-Peixoto and Talim, 2019; Flanagan and Weinshenker, 2014; Weinshenker and Wingerchuk, 2017; Waters et al., 2012; Jarius and Wildemann, 2013; Papais-Alvarenga et al., 2015). Based on class III-IV evidence, guideline recommendations for first, second and third-line maintenance treatments have been published (Palace et al., 2012; Trebst et al., 2014; Sellner et al., 2010). In addition, there is no standard management strategy for selection of first-line treatment or treatment switching. Based on these three new clinical trials (Pittock et al., 2019; Cree et al., 2019; Yamamura et al., 2019), more appropriate treatment strategies can probably be defined in the near future. The characteristics of recommended IST treatment options for NMOSD patients in LATAM are summarized in Table 3.

-Azathioprine (AZA; 2-3 mg/kg/day divided into 2-3 doses per day) has been shown to be effective and safe for preventing relapses of NMOSD and for decreasing disability, and therefore it can be used as a treatment for NMOSD.

AZA was shown to be effective and safe in previous studies that evaluated NMOSD patients (Bichuetti et al., 2010; Costanzi et al., 2011; Elsone et al., 2014; Qiu et al., 2015), including in a Brazilian cohort recently published (Bichuetti et al., 2019). In a prospective randomized controlled trial (Nikoo et al., 2017), use of AZA gave rise to significant decreases in both mean annualized relapse rate (ARR; 54% of the patients became relapse free after one year) and disability measured using EDSS (from 2.40 to 1.95). Regarding comparative effectiveness between AZA, RTX and MMF, retrospective studies found that RTX and MMF were more efficacious than AZA (Stellmann et al., 2017; Mealy et al., 2014; Jeong et al., 2016). Although there is a general consensus across all the currently published NMOSD guidelines that AZA is effective for treating NMOSD, the panel recommends starting treatment of NMOSD with RTX or MMF if available, while leaving AZA for milder disease or situations in which neither RTX nor MMF is available.

-NMOSD patients under treatment with AZA at a target dose of 2.5-3.0 mg/kg/day adjusted to the total lymphocyte count (< 600-1000/μL) and a mean corpuscular volume increase of at least 5 points from the baseline, who present a relapse after six months of therapy within five years of starting are classified as having "suboptimal treatment response".

If AZA is used correctly (early initiation, adequate dosing and adequate adherence to treatment) and a relapse is confirmed after 6 months of drug therapy, a suboptimal response to treatment should be considered, and the dose used could be increased until optimal monitoring doses are reached (lymphocytes count between 600-1000/μl or a mean corpuscular volume > 5 points compared to baseline) (Palace et al., 2012; Collongues et al., 2019; Mealy et al., 2014). The predominantly relapsing and often severe disease course of the disease supports the use of long-term preventive treatments in patients with NMOSD (Wingerchuk et al., 2007; Palace et al., 2012; Trebst et al., 2014; Sellner et al., 2010). Furthermore, the time to next attack can increase naturally in the later stages of the disease (Kim et al., 2013) suggesting the possible natural change in the disease activity over time (Kim et al., 2011). However, the duration of preventive treatment in NMOSD that is needed has not been adequately studied. Absence of new clinical relapses during an extended period of preventive therapy (e.g., more than 2 years) is viewed as probable treatment success. The absence of validated therapeutic biomarkers for NMOSD have suggested that AQP4-ab-positive patients who present with a first ever attack of LETM should be treated with immunosuppression for five years (Weinshenker et al., 2006; Kimbrough et al., 2012). This time period is arbitrary but attempts to balance the potential benefits of therapy during a period of higher relapse risk (the first 2-3 years after presentation) against the risks of long-term toxicity, especially treatment related to malignancy.

-Mycophenolate mofetil (MMF, at a target dose of 2-3 g/day divided into two doses per day) has been shown to be effective and safe for preventing relapse of NMOSD and for decreasing disability, and therefore it can be used as a first-line treatment for NMOSD patients.

-NMOSD patients under treatment with MMF at doses between 1500 and 3000 mg/day, adjusted based on the total lymphocyte count (> 1000/μL), who present a relapse after six months of drug therapy within five years of treatment start are classified as having a "suboptimal treatment response".

MMF is widely available around the world but, compared with AZA, it is more expensive (Bichuetti et al., 2019). MMF has been shown to be effective and safe in retrospective studies on NMOSD patients. Compared with AZA, MMF showed fewer side effects with more efficacy (Jacob et al., 2009; Huh et al., 2014; Montcuquet et al., 2017; Huang et al., 2019, 2018; Yang et al., 2018; Chen et al., 2017). In a recent systematic review and meta-analysis, MMF was ranked as a more tolerable therapy, compared with AZA and RTX (Huang et al., 2019). If a relapse is observed during MMF treatment, it is important to confirm whether MMF is being optimally dosed or whether increasing it to a maximum maintenance dose of 3000 mg/day is necessary. However, in a recent study, it was reported that 50.7% of patients experienced relapse under MMF treatment (Montcuquet et al., 2017). Nonetheless, 59.7% of them continued to receive MMF and 83% achieved stabilization or improvement of EDSS by the end of the follow-up. It was concluded that relapse under treatment should not be the only parameter for assessing treatment efficacy in NMOSD (Montcuquet et al., 2017). In general, if a relapse ("suboptimal treatment response") (Abboud et al., 2016) or ≥ 2 relapses or ≥ 1 severe relapse ("poor response") (Kim et al., 2017) is confirmed while patients are on MMF or AZA, they must switch the treatment.

In NMOSD patients who receive AZA or MMF, oral steroid tapering should be maintained for at least 4-6 months.

If AZA or MMF is added as long-term IST therapy, concomitant use of oral steroids for six months and tapering over the next six months is recommended in order to prevent relapses while another steroid-sparing therapy reaches full efficacy (Flanagan, 2019; Lana-Peixoto and Talim, 2019; Flanagan and Weinshenker, 2014; Weinshenker and Wingerchuk, 2017; Palace et al., 2012; Trebst et al., 2014; Sellner et al., 2010).

-Low doses of oral steroids (5–10 mg of prednisolone or its equivalent) should be administered for a prolonged period in combination with MMF/AZA in NMOSD patients who have "suboptimal treatment response".

Although general agreement for this statement was obtained, some of the panel members mentioned that "use of oral steroids should be decided on a case-by-case basis". On the one hand, they commented: "in patients with partial response to AZA/MMF, oral steroids in combination may be an acceptable approach", on the other hand, "suboptimal therapeutic response should lead to prompt and immediate change in immunotherapy and not to administering steroids in association".

In a prospective 18-month cohort trial, it was reported that combination of AZA with oral steroids led to benefits with regard to preventing relapse and improving disability (Mandler et al., 1998). In addition, low doses of oral steroids as monotherapy have been reported as having long-term beneficial effects with regard to reducing relapses

Table 3
Recommended immunosuppressant treatment options for NMOSD patients from Latin America

Medication, route and dosage	Mode of action	Efficacy/Effectiveness	Main examinations and monitoring	Most common and important side effects	Recommendations and comments
Oral steroids (OS): meprednisone / prednisone (Palace et al., 2012, Trebst et al., 2014, Sellner et al., 2010, Mandler et al., 1998, Watanabe et al., 2007) Oral Start at 60 mg once daily and then taper Target dose: 30-60 mg once a day	Binding to intracellular receptors which then act to modulate gene transcription	ARR was significantly lower (0.49 vs. 1.48 per year) in the OS periods (19.3 mo) than in the non-OS periods (45.3 mo)	Systematically evaluate for blood pressure, glycemia, electrolytes and bone density	Infections, weight gain and edema, hyperglycemia, hypertension, gastric irritation, insomnia, psychosis, rash, avascular necrosis of the hip and cushingoid appearance	If adding MMF or AZA, we recommended OS for 6 mo and then taper over 6 mo. Consider maintenance of 10-20 mg/day of OS if necessary. If adding RTX, we recommended OS for at least 1 mo and then taper OS could be used during pregnancy
Azathioprine (AZA) (Palace et al., 2012, Trebst et al., 2014, Sellner et al., 2010, Bichuetti et al., 2010, Costanzi et al., 2011, Elsone et al., 2014, Qiu et al., 2015, Bichuetti et al., 2019, Nikoo et al., 2017, Stellmann et al., 2017, Mealy et al., 2014, Jeong et al., 2016) Oral Inpatient (IP): Start 25 mg and then increase by 25 mg daily Outpatient (OP): Start 25 mg daily and then increase by 50 mg weekly. Target dose: 2500-3000 mg/Kg/ daily in divided doses	Inhibits purine synthesis resulting in the inhibition of DNA, RNA, and protein synthesis	Free of relapse: 34%–61% Follow-up (FU): 18–47 mo EDSS (stabilization or improvement): up to 69% during 5 years of FU	Pre-treatment: renal function, CBC and LE (both monthly for 6 mo and then twice a year) TMPT testing. If deficiency is confirmed, AZA should be avoided	Infections, diarrhea, vomiting, increased LE, rash, hypersensitivity Risk of malignancy depending on the used time (lymphoma, skin cancers and other cancers) may be increased Bone marrow suppression	AZA was recommended if unavailable MMF or RTX AZA should be combined with OS until its full effect (at least 6 months). Lymphopenia or an elevated MCV are a useful marker of adequate dose TPMT activity and metabolites could help to monitor the use of AZA AZA could be used during pregnancy
Mycofenolate mofetil (MMF) (Palace et al., 2012, Trebst et al., 2014, Sellner et al., 2010, Jacob et al., 2009, Huh et al., 2014, Montcuquet et al., 2017, Huang et al., 2019, Huang et al., 2018, Yang et al., 2018, Chen et al., 2017) Oral Start at 500 mg twice daily for 1–2 weeks and then increase to 1 g twice a day). Target dose: 750-1500 mg twice a day (median dose: 1g twice a day)	Prodrug of mycophenolic acid, an inhibitor of inosine-5′-monophosphate dehydrogenase (antimetabolite)	Free of relapse: 46%–73% FU: 20–27 mo EDSS (stabilization or improvement): up to 90% during 5 years of FU	Pre-treatment: renal function, CBC and LE (both monthly for 6 months and then twice a year)	Leucopenia, diarrhea, vomiting and sepsis Risk of malignancy (lymphoma, skin cancers and other cancers) may be increased Teratogenicity	MMF should be combined with OS until its full effect (at least 4–6 months). Lymphocyte count should decrease to 1000–1500/μL, following a plasma trough level of 1–2 μg/mL is a useful marker of adequate dose.
Rituximab (RTX) (Palace et al., 2012, Trebst et al., 2014, Sellner et al., 2010, Stellmann et al., 2017, Mealy et al., 2014, Jeong et al., 2016, Kim et al., 2013, Kimbrough et al., 2012, Montcuquet et al., 2017, Huang et al., 2019, Kim et al., 2015, Kim et al., 2011, Ciron et al., 2018, Damato et al., 2016, Torres et al., 2015, Zephir et al., 2015, Collongues et al., 2016, Jacob et al., 2008, Gao et al., 2019, Bedi et al., 2011, Kim et al., 2019, Shaygannejad et al., 2019, Marcinnò et al., 2018) Intravenous Induction: 1 g with re-treatment at 2 weeks or 375 mg/m2 body surface area once weekly for 4 weeks. Maintenance: 1 g with retreatment at 2 weeks every 6 mo or one infusion of 375 mg/m2 every 6 mo	Chimeric monoclonal antibody against human CD20	Free of relapse: 52%–88% FU: 24–60 mo. EDSS (stabilization or improvement): up to 97% during 5 years of FU	Pre-treatment: CBC, lymphocyte count, LE, serological antibody testing for HIV, HBV, HCV and VZV CBC, LE and memory B cells (CD19+/CD20+/CD27+) count at 3, 6 mo or if relapse. Immunoglobulin levels prior every dose	Minor infections (urinary and respiratory tract) Non-serious infusion-related reactions HBV and TBC reactivations	We recommended use concurrently of OS for at least 1 mo and then tapering Monitoring B cells (CD19+/CD20+/CD27+) could be useful to plan retreatment RTX could be used during pregnancy or overlapping syndrome (NMOSD and MS)

(*continued on next page*)

Table 3 (*continued*)

Medication, route and dosage	Mode of action	Efficacy/Effectiveness	Main examinations and monitoring	Most common and important side effects	Recommendations and comments
Eculizumab (ECZ) (Pittock et al., 2019) Intravenous 900 mg weekly during the first four doses starting on day 1, followed by 1200 mg every 2 weeks starting at week 4.	Humanized monoclonal antibody, which inhibits the terminal complement protein C5	Free of relapse: 96.1% FU: 96-weeks Relapse reduction: 93.1% EDSS (stabilization or improvement): not differences vs placebo	Pretreatment: ECG, pregnancy tests, chest X-ray, immunogenicity as measured by HAHA CBC, complete chemistry panel and urinalysis	Minor infections (respiratory tract, nasopharyngitis and urinary), headache. Non-serious infusion-related reactions. Increased risk of meningococcal and encapsulated bacterial infection	PREVENT trial was a randomized, placebo-controlled, time-to-event trial in AQP4-ab-positive NMOSD patients (add-on therapy) All NMOSD patients must receive meningococcal vaccination 14 days prior to the first dose
Satralizumab (Yamamura et al., 2019, Seze et al., 2020) Subcutaneous 120 mg at weeks 0, 2, and 4 and then every 4 weeks	Humanized anti interleukin 6 receptor (IL-6R) monoclonal antibody type IgG2 (recycling technology)	Free of relapse: 81% (+ AQP4-ab) and 72% (- AQP4-ab) FU: 96-weeks Relapse reduction: 58% EDSS (stabilization or improvement): NA	CBC, LE, complete chemistry panel and urinalysis serological antibody testing for HIV, HBV, HCV and latent TBC. Pregnancy test	Minor infections Non-serious infusion-related reactions	We show data from pooled analysis from two phase 3, randomized, double-blind, placebo-controlled studies in + and - AQP4-ab NMOSD patients. Sakura-Sky was an add-on therapy study (with AZA, MMF or OS) Sakura-Start was a monotherapy study
Inebilizumab (Cree et al., 2019) Intravenous 300 mg in 2 doses on open-label days 1 and 15 and then 300 mg every 6 mo	Humanized monoclonal antibody against CD19	Free of relapse: 87.6% FU: 28-weeks Relapse reduction: 73% EDSS (stabilization or improvement): OR = 0.37	Pre-treatment: CBC, lymphocyte count, LE and serological antibody testing for HIV, HBV, HCV and VZV.	Minor infections (urinary and respiratory tract) Non-serious infusion-related reactions. Arthralgia	N-MOmentum was a double-blind, randomized placebo-controlled phase 2/3 trial in + and - AQP4-ab NMOSD patients
Tocilizumab (TCZ) (Zhang et al., 2020, Lotan et al., 2019) Intravenous 8 mg/kg every 4 weeks	Humanized monoclonal antibody against the interleukin-6 receptor	Free of relapse: 91.5% FU: 48-weeks Relapse reduction: NA EDSS (stabilization or improvement): OR = 0.34	Pretreatment: CBC, LE and latent TBC evaluation CBC and LE every 1-2 mo for 3 mo and then quarterly. Blood pressure	Anemia, infusion-related reactions, infections (TBC, opportunistic), elevated LE, hypertension	TANGO was a randomized, open-label, parallel-group study comparing TCZ vs AZA in + and - AQP4-ab NMOSD patients TCZ could be considered in pregnant women with severe NMOSD

ARR: annualized relapse rate; DNA: deoxyribonucleic acid; RNA: ribonucleic acid; mo: month/s; CBC: complete blood cell count; LE: liver enzymes (aspartate aminotransferase and alanine aminotranferase); TMPT: thiopurine methyltransferase enzyme; MCV: mean corpuscular volume; HIV: human immunodeficiency virus; HBV: hepatitis B-virus; HCV: hepatitis C-virus; VZV: varicella zoster-virus; TBC: tuberculosis; NMOSD: neuromyelitis optica spectrum disorders; MS: multiple sclerosis; ECG: electrocardiogram; HAHA: Human Anti-human Antibody; NA: not available.

in NMOSD. Relapses were significantly more frequently with 10 mg/day or less, than with over 10 mg/day (OR = 8.75) (Watanabe et al., 2007).

-Induction protocol with RTX should be based on infusion of doses of 375 mg/m^2 of body surface area, administered as an i.v. infusion once a week for four weeks, or 1000 mg i.v. with re-treatment at 14 days.

-Maintenance protocols with 1000 mg of RTX with a re-treatment at 14 days or one infusion of 1000 mg or one infusion of 375 mg/m^2 repeated every six months have been shown to be safe and effective for preventing NMOSD relapses and therefore can be used as the standard protocol for treating NMOSD patients.

RTX is not widely available in LATAM. Compared with AZA or MMF, it is more expensive (Bichuetti et al., 2019). RTX has been shown to be effective and safe in prospective and retrospective studies on NMOSD patients (Collongues et al., 2019; Stellmann et al., 2017; Mealy et al., 2014; Jeong et al., 2016; Montcuquet et al., 2017; Huang et al., 2019; Kim et al., 2017, 2015, 2011; Ciron et al., 2018; Damato et al., 2016; Torres et al., 2015; Zephir et al., 2015; Collongues et al., 2016; Jacob et al., 2008; Gao et al., 2019; Bedi et al., 2011). Several comparative studies have demonstrated that RTX is more effective than AZA and MMF in decreasing relapse severity and preventing relapses (Collongues et al., 2019; Stellmann et al., 2017; Mealy et al., 2014; Jeong et al., 2016; Montcuquet et al., 2017; Huang et al., 2019; Kim et al., 2017, 2015, 2011; Ciron et al., 2018; Damato et al., 2016; Torres et al., 2015; Zephir et al., 2015; Collongues et al., 2016; Jacob et al., 2008; Gao et al., 2019; Bedi et al., 2011).

Although some recommendation guidelines have suggested that RTX may be used as a first-line treatment (Palace et al., 2012; Trebst et al., 2014; Sellner et al., 2010), its high cost and the lack of head-to-head studies limit access to this treatment in many LATAM countries (Bichuetti et al., 2019). In this regard, some neurologists only use RTX treatment in patients who fail to respond or do not respond to first-line treatments like AZA or MMF (Collongues et al., 2016). Notably, RTX may decrease the invisible costs of NMOSD patients who potentially would have experienced poor responses to AZA or MMF, since its use will reduce the number of hospitalizations because of decreased ARR, less use of paraclinical examinations like MRI and laboratory tests, less use of IVMP and less need for rehabilitation due to relapses (Palace et al., 2012; Trebst et al., 2014; Sellner et al., 2010).

There is no standardized RTX protocol for NMOSD. No differences in efficacy between induction protocols has been reported, given that retreatment was properly performed based on pre-planned B cell monitoring (Kim et al., 2011). To minimize potential side effects during follow-up, recent guidelines on use of RTX for treating NMOSD recommended use of 1000 mg every 6 months during follow-up (Collongues et al., 2019; Ciron et al., 2018; Kim et al., 2019).

One alternative to a fixed-dosage protocol every 6 months is to monitor memory B cell counts (CD19+/CD20+/CD27+) at three and six months and at any time if relapse is confirmed (Costanzi et al., 2011; Kim et al., 2013). If easy access to CD27+ cell counts is not possible, counting only the total CD19+ cells is an acceptable evaluation (Collongues et al., 2019; Ciron et al., 2018; Kim et al., 2019). In a prospective study and metanalysis (n = 438), around 30% of the patients treated with RTX had side effects (Damato et al., 2016; Shaygannejad et al., 2019). Minor infections (urinary and respiratory tract) and non-serious infusion-related reactions were the most frequent of these (Damato et al., 2016). In addition, long-term RTX treatment has been associated with the risk of hypogammaglobulinemia (Marcinnò et al., 2018). In another metanalysis (n = 577), 16.4% of the patients undergoing RTX treatment experienced side effects (2% of them had severe side effects) and 0.9% died (Gao et al., 2019).

IVMP at 100 mg for 60 min prior to RTX infusion has been demonstrated to mitigate the risk of infusion-related side effects (Ciron et al., 2018). A French consensus (Ciron et al., 2018) recommended a combination of steroids with IV antihistamine and paracetamol, but without clear evidence. All immunizations (especially influenza vaccine, pneumococcal vaccine, varicella zoster virus vaccine and hepatitis B and C vaccine) included in the vaccination schedule should be highlighted (Ciron et al., 2018; Kim et al., 2019).

-In NMOSD patients who receive RTX, oral steroids should be maintained for at least 1-2 months after starting RTX.

If RTX is used following a relapse, concurrent use of oral steroids for at least 1 month, followed by tapering. This is because RTX treatment could be followed by relapses in the first month (Perumal et al., 2015), possibly because of induction of B-cell activating factor, thus resulting in a transient increase in AQP4-ab titers or lysis of B cells (Flanagan and Weinshenker, 2014; Perumal et al., 2015; Nakashima et al., 2011).

Regardless of the number and severity of relapses among NMOSD patients after treatment starts, occurrences of relapses after at least six months of correct use of the specific treatment indicates that disease activity still persists and justifies modifying the therapeutic scheme to balance the risk and benefit.

Although there is a consensus that NMOSD patients need to receive long-term IST, the best treatment choice for each individual remains uncertain. No comparisons have been made among these drugs in head-to-head studies and the terms “suboptimal treatment response”, “poor response” and “treatment failure” have not been clearly defined. Based on experience in clinical practice, if a relapse is confirmed while IST treatment is underway with correct use and dosage (Mealy et al., 2014; Kim et al., 2017), these patients should be switched to a drug with a different mechanism of action because persistence of disease activity exists. Definitions of effective therapeutic protocols for NMOSD patients resistant to IST drugs are still required.

NMOSD patients under treatment with RTX who present a relapse after 1 to 5 months are considered to have a "suboptimal treatment response".

If the NMOSD diagnosis is confirmed and RTX is chosen, this treatment should be started immediately following IVMP or PLEX treatment for relapse and oral steroids. It should be maintained for at least 1 month (Ciron et al., 2018) and then tapered off. Different strategies to evaluate long-term RTX management have been described (Collongues et al., 2019; Ciron et al., 2018; Kim et al., 2019). In general, the clinical response to RTX in NMOSD patients depends on the degree of B cell depletion, regardless of the dose of rituximab used (Kim et al., 2019). The degree and durability of B cell depletion in RTX treatment is variable (Cohen et al., 2017).

The first strategy consists of repeating RTX infusions every six months without other paraclinical monitoring of its effects (Collongues et al., 2019; Ciron et al., 2018; Kim et al., 2019). Given that the full effect of RTX is delayed for at least one month after infusion, NMOSD patients who have a relapse after this period (1 to 5 months) are considered as having a "suboptimal treatment response". Another strategy is to monitor CD19+ cells during the follow-up. CD19+ cells in blood have been shown to provide a good measurement of the total number of circulating B cells, and some neurologists have suggested repeating RTX infusions when CD19+ cell counts exceed 0.01×10^9/L (Collongues et al., 2019; Kim et al., 2019; Pellkofer et al., 2011) or when they reach more than 0.1% of the total lymphocyte count (Mealy et al., 2014). Other investigators have suggested monitoring CD27+ cells in peripheral blood, with the aim of repeating the treatment only when CD27+ cell levels are more than 0.05% of PBMCs (Collongues et al., 2019; Kim et al., 2011, 2019), since the risk of reactivation of the disease seems to be correlated with re-emergence of memory B cells (Collongues et al., 2019; Kim et al., 2019). Monitoring RTX infusion through AQP4-ab titers in AQP4-ab-positive NMOSD patients is not recommended.

Although there is no clear definition for “suboptimal treatment response”, if a relapse is confirmed in these patients while on RTX, they should be switched to a drug with a different mechanism of action, such as new drugs (eculizumab, satralizumab, inebilizumab or tocilizumab)

(Pittock et al., 2019; Cree et al., 2019; Yamamura et al., 2019; Ringelstein et al., 2015; Araki et al., 2014; Zhang et al., 2020; Lotan et al., 2019) or combination treatment (e.g. RTX plus MMF). However, only limited published data is available, particularly for this last strategy (Flanagan and Weinshenker, 2014). Although there is not much experience in the use of these new drugs in LATAM, they have been shown to be safe and effective in randomized placebo-controlled trials (Pittock et al., 2019; Cree et al., 2019; Yamamura et al., 2019). However, caution is needed in making decisions about treatment failure or suboptimal treatment.

Tocilizumab can be used in NMOSD patients showing no response to other immunosuppressants in clinical practice.

Eculizumab can be used in NMOSD patients showing no response to other immunosuppressants in clinical practice.

Inebilizumab can be used in NMOSD patients showing no response to other immunosuppressants in clinical practice.

Satralizumab can be used in NMOSD patients showing no response to other immunosuppressants in clinical practice.

There has been a gap of nearly 100 years in progress with research into understanding the pathophysiology of NMOSD. Thus, new therapeutic approaches with different modes of action and routes of administration have been shown to be effective for treating NMOSD patients.

Tocilizumab (anti-IL-6R) has been shown to significantly reduce the risk of new relapses, in comparison with AZA (Zhang et al., 2020). Most recently, subcutaneous tocilizumab treatment has also seen to have effectiveness similar to that of intravenous formulations (Lotan et al., 2019). As previously mentioned, monoclonal antibodies such as eculizumab (anti-complement protein C5) (Pittock et al., 2019), inebilizumab (anti-CD19) (Cree et al., 2019) and satralizumab (anti-IL-6R) (Yamamura et al., 2019; Seze et al., 2020) have been shown to significantly reduce the risk of new relapses, in comparison with placebo (especially in AQP4-ab-positive patients), with clinical stabilization or improvement in most of them. Additionally, all these drugs have demonstrated good safety and tolerability profiles with a limited rate of side effects. At the present time, eculizumab has become the first drug approved for NMOSD. Other treatments for NMOSD will probably be approved in the near future. IST treatment options for NMOSD patients are summarized in Table 3.

For severely disabling clinical symptoms or life-threatening relapses (highly active disease), cyclophosphamide or mitoxantrone can be used as induction therapy followed by a maintenance protocol after failure of RTX or when RTX is unavailable.

RTX is not effective for all NMOSD patients, and therefore other treatment options should be considered, including cyclophosphamide and mitoxantrone (Palace et al., 2012; Trebst et al., 2014; Sellner et al., 2010; Collongues et al., 2019; Kimbrough et al., 2012).

Mitoxantrone has been shown to significantly reduce the rate of relapses in NMOSD patients (Kim et al., 2015). However, due to its side effects, particularly cardiotoxicity and myelotoxicity, and because other therapeutic alternatives with fewer side effects are available, its use should be considered very critically (Palace et al., 2012; Trebst et al., 2014; Sellner et al., 2010; Collongues et al., 2019; Kimbrough et al., 2012; Weinstock-Guttman et al., 2006). Panels of experts on NMOSD treatment have recommended that cyclophosphamide should only be used when other IST treatments fail or are not available (Palace et al., 2012; Trebst et al., 2014; Sellner et al., 2010; Kimbrough et al., 2012; Mok et al., 2008). The treatment may be applied in immunoablative doses (2000 mg/day for 4 days) or at a dose of 600 mg/m^2 (Palace et al., 2012; Trebst et al., 2014; Sellner et al., 2010; Collongues et al., 2019; Mok et al., 2008).

Routine brain MRI among NMOSD patients after specific treatment has been started is recommended at least once a year to identify ongoing inflammatory disease activity.

Follow-up brain MRI in NMOSD patients once a year is recommended in order to evaluate disease activity, since MRI shows demyelinating lesions more sensitively than do clinical manifestations (Kim et al., 2016; Geraldes et al., 2018). As observed in a LATAM population (Carnero Contentti et al., 2018), several studies have shown that T2-signal abnormalities in the brain exist in up to 80% of NMOSD patients at presentation or during follow-up (Wingerchuk et al., 2007; Kim et al., 2015; Carnero Contentti et al., 2018; Matthews et al., 2013; Geraldes et al., 2018). In general, these lesions are often clinically silent (Wingerchuk et al., 2007), commonly not classically oval shaped (i.e. unlike those reported in MS), and typically are not visible on T1-weighted images (Wingerchuk et al., 2007; Kim et al., 2015; Carnero Contentti et al., 2018; Matthews et al., 2013; Comi et al., 2017; Pittock et al., 2006). The association that brain MRI lesions might have as a predictor of future disease activity and disability is still unclear. Recently, the central vein sign (CVS); in which MS lesions are developed around small veins was reported as a specific marker for MS diagnosis (Sati et al., 2016; Gaitán et al., 2020). A sensitivity of 68.1% and specificity of 82.9% for distinguishing MS from not MS using a 35% CVS proportion threshold has been reported (Sinnecker et al., 2019). Recently, a Class III study provided evidence that the proportion of lesions with the CVS was significantly higher in MS than in AQP4-ab-positive NMOSD patients (80% vs 32%, $p < 0.001$) (Cortese et al., 2018). If more than 54% of the lesions on any given scan show the CVS, then the patient can be given a diagnosis of MS with an accuracy of 94% (Cortese et al., 2018).

Regarding the brain MRI at six months after starting a specific treatment, the panel did not reach any consensus for recommending this. The panel members commented that brain MRI is not necessary if clinical relapses are not present during this period, unlike MS. However, future studies and evidence could modify this recommendation. The panel also did not reach any consensus regarding the necessity for an annual spinal cord MRI (routine) after starting a specific treatment, for identifying ongoing disease activity. The panel highlighted the absence of benefit from monitoring clinically silent lesions spinal cord MRI for NMOSD patients, as seen in MS (Comi et al., 2017).

2.7. Recommendations in special situations

For NMOSD patients whose phenotype is indeterminate between MS and NMOSD (overlapping syndrome), RTX is recommended.

When diagnostic uncertainty exists between MS and NMOSD, particularly in anti-AQP4-ab-negative NMOSD patients, it should be considered that the published expert recommendations state that an NMOSD-suitable IST strategy will be effective for both diseases (Weinshenker and Wingerchuk, 2017; Palace et al., 2012). Although RTX is an off-label treatment for both MS and NMOSD, it has been shown to be effective in diminishing the rate of relapses in both diseases, over variable follow-up durations.

Early IVMP treatment (1 g daily for 3–5 days) in situations of acute relapse during pregnancy (depending on relapse severity) is recommended.

Women with NMOSD can remain active during pregnancy and it has been reported that they are at increased risk of relapses during the first 3 months (Nour et al., 2016; Fragoso et al., 2013; Klawiter et al., 2017; Shimizu et al., 2016; Huang et al., 2017) and 6 months (Kim et al., 2012) postpartum compared with pre-pregnancy. Furthermore, they can present poor pregnancy outcomes, particularly if they are AQP4-ab-positive (Shimizu et al., 2016; Delgado-García et al., 2018). Nevertheless, higher rates of miscarriage and preeclampsia are still controversial (Nour et al., 2016; Delgado-García et al., 2018; Salvador et al., 2019). During pregnancy, a personalized treatment regimen is required, because there are no treatment guidelines based on controlled clinical studies for this situation. We recommend treatment of acute NMOSD relapses during pregnancy or breastfeeding, consisting of IVMP 1 g day for 3-5 days (mothers should wait for 1-4 hours before they start breastfeeding again). In addition, oral steroids may be continued during pregnancy in NMOSD (Shosha et al., 2017; Borisow et al.,

2018; Mao-Draayer et al., 2020) at the lowest possible dose, typically less than 20 mg/day, using steroids that do not cross the placenta. In several studies, IVMP (short-term treatment) was used during pregnancy without apparent complications affecting the fetus, except for low birth weight (Nour et al., 2016; Fragoso et al., 2013; Klawiter et al., 2017; Shimizu et al., 2016; Huang et al., 2017; Kim et al., 2012; Delgado-García et al., 2018; Salvador et al., 2019; Shosha et al., 2017; Borisow et al., 2018; Mao-Draayer et al., 2020).

Early PLEX treatment in situations of acute relapse during pregnancy (depending on relapse severity) should be considered.

PLEX may be used during pregnancy to treat relapses of NMOSD, particularly for episodes in women who do not respond to corticosteroids (Jacob et al., 2008; Gao et al., 2019; Bedi et al., 2011; Kim et al., 2019; Shaygannejad et al., 2019; Marcinnò et al., 2018; Perumal et al., 2015). PLEX and immunoadsorption seem to be relatively safe during pregnancy and can be used after evaluating the risk-benefit relationship (Shosha et al., 2017; Borisow et al., 2018; Mao-Draayer et al., 2020).

On the other hand, monthly IVIG seem to be a relatively safe option if needed (e.g. in cases of contraindication for IVMP or PLEX), but very little evidence of efficacy exists (Shosha et al., 2017; Borisow et al., 2018; Mao-Draayer et al., 2020).

Immunosuppressive therapy with AZA or RTX during pregnancy should be continued if the patient has had attacks of NMOSD within the past 3 years.

Given that some studies have demonstrated that women with NMOSD with more active disease may have more complications, IST treatment is recommended (Nour et al., 2016; Shosha et al., 2017; Borisow et al., 2018; Mao-Draayer et al., 2020).

Based on expert opinion, AZA and RTX treatment should be continued in NMOSD patients with active disease (i.e. those with frequent and disabling relapses) throughout pregnancy and the postpartum period after careful risk-benefit evaluation (Shosha et al., 2017; Borisow et al., 2018; Mao-Draayer et al., 2020). For RTX, conception immediately after the last infusion might be acceptable. Retreatment should be administered if no pregnancy is confirmed within six months and re-dosing, if severe relapses occur during pregnancy (Mao-Draayer et al., 2020). For AZA, continuing with a dose of 2.5 mg/kg/day or in combination with low doses of oral steroids seems to be safe and reasonable if disease activity exists (Shosha et al., 2017).

More than 2000 cases of AZA use during pregnancy have been reported (Shosha et al., 2017; Borisow et al., 2018; Mao-Draayer et al., 2020). Although reduced rates of preterm birth, low birth weight and cardiac septal defects were informed, these defects might have been due to underlying diseases in the mother, which might have led to taking AZA (Shosha et al., 2017; Borisow et al., 2018; Mao-Draayer et al., 2020).

RTX treatment during the first trimester has been studied in mothers with a variety of conditions (mainly non-Hodgkin lymphoma and rheumatoid arthritis). In this population, miscarriages, congenital malformation and premature birth were observed at percentages higher than in the general population (Shosha et al., 2017; Borisow et al., 2018; Mao-Draayer et al., 2020). This finding might also have a relationship with underlying diseases in the mothers (Shosha et al., 2017; Borisow et al., 2018; Mao-Draayer et al., 2020). However, in a systematic review that evaluated pregnant women under RTX exposure within six months of conception or during pregnancy (Shosha et al., 2017; Borisow et al., 2018; Mao-Draayer et al., 2020), no increased risk of birth defects was found but there was a possibility that B cell depletion in the fetus would occur. In a French consensus on RTX use, it was recommended that effective contraceptive methods during and for six months after RTX treatment should be used (Ciron et al., 2018).

Funding

This research did not receive any specific grant.

Declaration of Competing Interest

EC has received reimbursement for developing educational presentations, educational and research grants, consultation fees and/or travel stipends from Biogen, Genzyme, Merck and Novartis.

JIR has received honoraria from Novartis as a scientific advisor. He has received travel grants and attended courses and conferences on behalf of Merck-Serono Argentina, Novartis Argentina

EC has received reimbursement for developing educational presentations, educational and research grants, consultation fees and/or travel stipends from Biogen, Novartis, Genzyme, Merck and Roche.

VDM has received reimbursement for developing educational presentations, educational and research grants, consultation fees and/or travel stipends from Biogen Idec, Merck-Serono, Novartis, Roche, Sanofi-Genzyme, Teva.

JFR has nothing to disclose.

MLP has received reimbursement for developing educational presentations, educational and research grants, and travel stipends from Biogen Idec, Roche, Novartis and Sanofi-Aventis.

CN has nothing to disclose.

RPA has received reimbursement for developing educational presentations, educational and research grants, consultation fees and/or travel stipends from the following pharmaceuticals industries: Teva, Novartis, Roche, Merck, Biogen and Sanofi.

DKS has received research support from CNPq/Brazil (425331/2016-4 and 308636/2019-8), FAPERGS/MS/CNPq/SESRS (17/2551-0001391-3) PPSUS/Brazil, TEVA, Merck and Euroimmun AG for investigator-initiated studies; has received speaker honoraria from Biogen, Novartis, Genzyme, TEVA, Merck, Roche and Bayer and has participated in advisory boards for Shire, Roche, TEVA, and Merck. ISC has received reimbursement for developing educational presentations, educational and research grants, consultation fees and/or travel stipends from the following pharmaceuticals industries: Teva, Bayer, and Biogen. JC is a board member of Merck-Serono Argentina, Novartis Argentina, Genzyme LATAM, Genzyme global, Biogen-Idec LATAM and Merck-Serono LATAM. He is part of the Steering Committee for the clinical trials of Ofatumumab (Novartis Global). JC has received reimbursement for developing educational presentations for Merck-Serono Argentina, Merck-Serono LATAM, Biogen-Idec Argentina, Genzyme Argentina, Novartis Argentina, Novartis LATAM, Novartis Global and Roche Argentina, as well as professional travel/accommodation stipends.

Acknowledgement

We would like to thank Prof. Brian G. Weinshenker (Department of Neurology, Mayo Clinic, USA) for his valuable recommendations and support provided during the development of this project.

Supplementary materials

Supplementary material associated with this article can be found, in the online version, at doi:10.1016/j.msard.2020.102428.

References

Abboud, H, Petrak, A, Mealy, M, et al., 2016. Treatment of acute relapses in neuromyelitis optica: steroids alone versus steroids plus plasma exchange. Mult. Scler. 22, 185–192.
Alvarenga, MP, Schimidt, S, Alvarenga, RP, 2017. Epidemiology of neuromyelitis optica in Latin America. Mult. Scler. J. Exp. Transl. Clin. 3 (3), 2055217317730098.
Amaral, JM, Talim, N, Kleinpaul, R, Lana-Peixoto, MA, Brazilian Committee for Treatment and Research in Multiple Sclerosis, 2020. Optic neuritis at disease onset predicts poor visual outcome in neuromyelitis optica spectrum disorders. Mult. Scler. Relat. Disord. 41, 102045.
Araki, M, Matsuoka, T, Miyamoto, K, et al., 2014. Efficacy of the anti-IL-6 receptor antibody tocilizumab in neuromyelitis optica: a pilot study. Neurology 82, 1302–1306.
Asseyer, S, Schmidt, F, Chien, C, et al., 2018. Pain in AQP4-IgG-positive and MOG-IgG-positive neuromyelitis optica spectrum disorders. Mult. Scler. J. Exp. Transl. Clin. 4

(3), 2055217318796684.
Banerjee, A, Ng, J, Coleman, J, Ospina, JP, et al., 2019. Outcomes from acute attacks of neuromyelitis optica spectrum disorder correlate with severity of attack, age and delay to treatment. Mult. Scler. Relat. Disord. 28, 60–63 Feb.
Bedi, GS, Brown, AD, Delgado, SR, et al., 2011. Impact of rituximab on relapse rate and disability in neuromyelitis optica. Mult. Scler. 17, 1225–1230.
Beekman, J, Keisler, A, Pedraza, O, et al., 2019. Neuromyelitis optica spectrum disorder: patient experience and quality of life. Neurol. Neuroimmunol. Neuroinflamm. 6 (4), e580.
Bell, BG, Spencer, R, Avery, AJ, Campbell, SM, 2014. Tools for measuring patient safety in primary care settings using the RAND/UCLA appropriateness method. BMC Fam. Pract. 15, 110.
Bennett, JL, de Seze, J, Lana-Peixoto, M, et al., 2015. Neuromyelitis optica and multiple sclerosis: seeing differences through optical coherence tomography. Mult. Scler. 21 (6), 678–688 May;.
Bergamaschi, R, Tonietti, S, Franciotta, D, et al., 2004. Oligoclonal bands in Devic's neuromyelitis optica and multiple sclerosis: differences in repeated cerebrospinal fluid examinations. Mult. Scler. 10, 2–4.
Bichuetti, DB, Lobato de Oliveira, EM, Oliveira, DM, et al., 2010. Neuromyelitis optica treatment: analysis of 36 patients. Arch. Neurol. 67, 1131–1136.
Bichuetti, DB, Perin, MMM, Souza, NA, Oliveira, EML, 2019. Treating neuromyelitis optica with azathioprine: 20-year clinical practice. Mult. Scler. 25 (8), 1150–1161 Jul.
Birnbaum, J, Atri, NM, Baer, AN, et al., 2017. Relationship between neuromyelitis optica spectrum disorder and Sjögren's syndrome: central nervous system extraglandular disease or unrelated, co-occurring autoimmunity? Arthritis Care Res. (Hoboken) 69 (7), 1069–1075. https://doi.org/10.1002/acr.23107. Jul.
Bonnan, M, Cabre, P., 2012. Plasma exchange in severe attacks of neuromyelitis optica. Mult. Scler. Int. 2012, 787630.
Bonnan, M, Valentino, R, Debeugny, S, Merle, H, Ferge, JL, Mehdaoui, H, et al., 2018. Short delay to initiate plasma exchange is the strongest predictor of outcome in severe attacks of NMO spectrum disorders. J. Neurol. Neurosurg. Psychiatry 89 (4), 346–351.
Borisow, N, Hellwig, K, Paul, F, 2018. Neuromyelitis optica spectrum disorders and pregnancy: relapse-preventive measures and personalized treatment strategies. EPMA J. 9 (3), 249–256 Aug 10.
Bursztyn, LLCD, De Lott, LB, Petrou, M, Cornblath, WT, 2019. Sensitivity of orbital magnetic resonance imaging in acute demyelinating optic neuritis. Can. J. Ophthalmol. 54 (2), 242–246 Apr.
Carnero Contentti, E, Daccach Marques, V, Soto de Castillo, I, et al., 2018. Short-segment transverse myelitis lesions in a cohort of Latin American patients with neuromyelitis optica spectrum disorders. Spinal Cord. 56 (10), 949–954.
Carnero Contentti, E, Daccach Marques, V, Soto de Castillo, I, et al., 2018. Frequency of brain MRI abnormalities in neuromyelitis optica spectrum disorder at presentation: a cohort of Latin American patients. Mult. Scler. Relat. Disord. 19, 73–78.
Carnero Contentti, E, Daccach Marques, V, Soto de Castillo, I, et al., 2020. Clinical features and prognosis of late-onset neuromyelitis optica spectrum disorders in a Latin American cohort. J. Neurol. 267 (5), 1260–1268.
Carnero Contentti, E, De Virgiliis, M, Hryb, JP, et al., 2019. Aquaporin-4 serostatus and visual outcomes in clinically isolated acute optic neuritis. J. Neuroophthalmol. 39 (2), 165–169 Jun;.
Carnero Contentti, E, Giachello, S, Correale, J, 2020. Barriers to access and utilization of multiple sclerosis care services in a large cohort of Latin American patients [published online ahead of print, 2020 Jan 21]. Mult. Scler 1352458519898590.
Carnero Contentti, E, Leguizamón, F, Hryb, JP, Celso, J, Pace, JL, Ferrari, J, Knorre, E, Perassolo, MB, 2016 Oct; Oct. Neuromyelitis optica: association with paroxysmal painful tonic spasms. Neurologia 31 (8), 511–515.
Carnero Contentti, E, Marques, VD, Soto de Castillo, I, et al., 2019. Brain and spinal MRI features distinguishing MS from different AQP4 antibody serostatus NMOSD at disease onset in a cohort of Latin American patients. Mult. Scler May 241352458519849517.
Carnero Contentti, E, Sotode Castillo, I, Daccach Marques, V, et al., 2018. Application of the 2015 diagnostic criteria for neuromyelitis optica spectrum disorders in a cohort of Latin American patients. Mult. Scler. Relat. Disord. 20, 109–114.
Chen, H, Qiu, W, Zhang, Q, Wang, J, Shi, Z, Liu, J, et al., 2017. Comparisons of the efficacy and tolerability of mycophenolate mofetil and azathioprine as treatments for neuromyelitis optica and neuromyelitis optica spectrum disorder. Eur. J. Neurol. 24, 219–226.
Ciccarelli, O, Cohen, JA, Reingold, SC, Weinshenker, BG, International Conference on Spinal Cord Involvement and Imaging in Multiple Sclerosis and Neuromyelitis Optica Spectrum Disorders, 2019. Spinal cord involvement in multiple sclerosis and neuromyelitis optica spectrum disorders. Lancet Neurol. 18 (2), 185–197 Feb;.
Ciron, J, Audoin, B, Bourre, B, et al., 2018. Recommendations for the use of Rituximab in neuromyelitis optica spectrum disorders. Rev. Neurol. (Paris) 174 (4), 255–264 Apr.
Cohen, M., Romero, G., Bas, J., et al., 2017. Monitoring CD27+ memory B-cells in neuromyelitis optica spectrum disorders patients treated with rituximab: results from a bicentric study. J. Neurol. Sci. 373, 335–338.
Collongues, N, Ayme-Dietrich, E, Monassier, L, de Seze, J, 2019. Pharmacotherapy for neuromyelitis optica spectrum disorders: current management and future options. Drugs 79 (2), 125–142 Feb.
Collongues, N, Brassat, D, Maillart, E, et al., 2016. Efficacy of rituximab in refractory neuromyelitis optica. Mult. Scler. 22, 955–959.
Comi, G., Radaelli, M., Soelberg Sorensen, P., 2017. Evolving concepts in the treatment of relapsing multiple sclerosis. Lancet 389 (10076), 1347–1356.
Cortese, R, Magnollay, L, Tur, C, et al., 2018. Value of the central vein sign at 3T to differentiate MS from seropositive NMOSD. Neurology 90 (14), e1183–e1190.
Costanzi, C, Matiello, M, Lucchinetti, CF, et al., 2011. Azathioprine: tolerability, efficacy, and predictors of benefit in neuromyelitis optica. Neurology 77, 659–666.
Cree, BAC, Bennett, JL, Kim, HJ, et al., 2019. Inebilizumab for the treatment of neuromyelitis optica spectrum disorder (N-MOmentum): a double-blind, randomised placebo-controlled phase 2/3 trial. Lancet 394 (10206), 1352–1363 Oct 12.
Cristiano, E, Rojas, JI, Alonso, R, et al., 2020. Consensus recommendations on the management of multiple sclerosis patients in Argentina. J. Neurol. Sci. 409, 116609 Feb 15.
Damato, V, Evoli, A, Iorio, R, 2016. Efficacy and safety of rituximab therapy in neuromyelitis optica spectrum disorders: a systematic review and meta-analysis. JAMA Neurol. 73, 1342–1348.
Delgado-García, G, Méndez-Zurita, VA, Bayliss, L, Flores-Rivera, J, Fleury, A, 2019. Neurocysticercosis: mimics and chameleons. Pract. Neurol. 19 (2), 88–95.
Delgado-García, G., Chávez, Z., Rivas-Alonso, V., Corona, T., Flores-Rivera, J., 2018. Obstetric outcomes in a Mexican cohort of patients with AQP4-antibody seropositive neuromyelitis optica. Mult. Scler. Relat. Disord. 25, 268–270.
Drulovic, J, Martinovic, V, Basuroski, ID, Mesaros, S, Mader, S, Weinshenker, B, Pekmezovic, T, 2019. Long-term outcome and prognosis in patients with neuromyelitis optica spectrum disorder from Serbia. Mult. Scler. Relat. Disord. 36, 101413 Nov.
Elsone, L, Kitley, J, Luppe, S, et al., 2014. Long-term efficacy, tolerability and retention rate of azathioprine in 103 aquaporin-4 antibody-positive neuromyelitis optica spectrum disorder patients: a multicenter retrospective observational study from the UK. Mult. Scler. 20, 1533–1540.
Flanagan, EP, Weinshenker, BG, Krecke, KN, Lennon, VA, Lucchinetti, CF, McKeon, A, et al., 2015. Short myelitis lesions in aquaporin-4-IgG-positive neuromyelitis optica spectrum disorders. JAMA Neurol. 72, 81–87.
Flanagan, EP, Weinshenker, BG., 2014. Neuromyelitis optica spectrum disorders. Curr. Neurol. Neurosci. Rep. 14 (9), 483 Sep.
Flanagan, EP., 2019. Neuromyelitis optica spectrum disorder and other non-multiple sclerosis central nervous system inflammatory diseases. Continuum (Minneap Minn). 25 (3), 815–844.
Fragoso, YD, Adoni, T, Bichuetti, DB, et al., 2013. Neuromyelitis optica and pregnancy. J. Neurol. 260, 2614–2619.
Fragoso, YD, Elso, FG, Carrá, A, 2017. Differential diagnosis of multiple sclerosis in Latin America. Mult. Scler. J. Exp. Transl. Clin. 3 (3), 2055217317714279 Sep 25.
Fragoso, YD, Sousa, NAC, Alves-Leon, SV, et al., 2019. Clinical characteristics of 153 Brazilian patients with neuromyelitis optica spectrum disorder (NMOSD). Mult. Scler. Relat. Disord. 27, 392–396.
Fryer, JP, Lennon, VA, Pittock, SJ, et al., 2014. AQP4 autoantibody assay performance in clinical laboratory service. Neurol. Neuroimmunol. Neuroinflamm. 1 (1), e11 May 22.
Fujihara, K, Sato, DK, 2013. AQP4 antibody serostatus: is its luster being lost in the management and pathogenesis of NMO? Neurology 81, 1186–1188.
Gaitán, MI, Yañez, P, Paday Formenti, ME, et al., 2020. SWAN-venule: an optimized MRI technique to detect the central vein sign in MS plaques. AJNR Am. J. Neuroradiol. 41 (3), 456–460.
Gao, F, Chai, B, Gu, C, Wu, R, Dong, T, Yao, Y, Zhang, Y, 2019. Effectiveness of rituximab in neuromyelitis optica: a meta-analysis. BMC Neurol. 19 (1), 36 Mar 6;.
Geraldes, R, Ciccarelli, O, Barkhof, F, et al., 2018. The current role of MRI in differentiating multiple sclerosis from its imaging mimics [published correction appears in Nat Rev Neurol. 2018 Mar 20;14 (4):213]. Nat. Rev. Neurol. 14 (4), 199–213.
Ghezzi, A, Bergamaschi, R, Martinelli, V, et al., 2004. Clinical characteristics, course and prognosis of relapsing Devic's Neuromyelitis Optica. J. Neurol. 251 (1), 47–52 Jan.
Gray, D.J., Ross, A.G., Li, Y.-S., McManus, D.P., 2011. Diagnosis and management of schistosomiasis. BMJ 342, d2651.
Hamid, S.H., Elsone, L., Mutch, K., et al., 2017. The impact of 2015 neuromyelitis optica spectrum disorders criteria on diagnostic rates. Mult. Scler. 23 (2), 228–233.
Hamid, SHM, Whittam, D, Mutch, K, et al., 2017. What proportion of AQP4-IgG-negative NMO spectrum disorder patients are MOG-IgG positive? A cross sectional study of 132 patients. J. Neurol. 264 (10), 2088–2094.
Hor, JY, Asgari, N, Nakashima, I, et al., 2020. Epidemiology of neuromyelitis optica spectrum disorder and its prevalence and incidence worldwide. Front. Neurol 11, 501.
Hu, H, You, X, Ye, J, 2018. Short transverse myelitis in Chinese patients with neuromyelitis optica spectrum disorders. Mult. Scler. Relat. Disord. 21, 78–83.
Huang, Q, Wang, J, Zhou, Y, Yang, H, Wang, Z, Yan, Z, Long, Y, Yin, J, Feng, H, Li, C, Lu, Z, Hu, X, Qiu, W, 2018. Low-dose mycophenolate mofetil for treatment of neuromyelitis optica spectrum disorders: a prospective multicenter study in South China. Front. Immunol. 9, 2066 Sep 11.
Huang, W, Wang, L, Zhang, B, Zhou, L, Zhang, T, Quan, C, 2019. Effectiveness and tolerability of immunosuppressants and monoclonal antibodies in preventive treatment of neuromyelitis optica spectrum disorders: a systematic review and network meta-analysis. Mult. Scler. Relat. Disord. 35, 246–252 Oct;.
Huang, Y, Wang, Y, Zhou, Y, et al., 2017. Pregnancy in neuromyelitis optica spectrum disorder: a multicenter study from South China. J. Neurol. Sci. 372, 152–156.
Huh, SY, Kim, SH, Hyun, JW, et al., 2014. Mycophenolate mofetil in the treatment of neuromyelitis optica spectrum disorder. JAMA Neurol. 71, 1372–1378.
Huh, SY, Kim, SH, Hyun, JW, Jeong, IH, Park, MS, Lee, SH, et al., 2017. Short segment myelitis as a first manifestation of neuromyelitis optica spectrum disorders. Mult. Scler. 23, 413–419.
Hyun, J.W., Jeong, I.H., Joung, A., et al., 2016. Evaluation of the 2015 diagnostic criteria for neuromyelitis optica spectrum disorder. Neurology 86, 1772–1779.
Hyun, JW, Jang, H, Yu, J, Park, NY, Kim, SH, Huh, SY, Kim, W, Park, MS, Oh, J, Park, KD, Kim, HJ, 2020. Comparison of neuropathic pain in neuromyelitis optica spectrum disorder and multiple sclerosis. J. Clin. Neurol. 16 (1), 124–130.

Jacob, A, Matiello, M, Weinshenker, BG, et al., 2009. Treatment of neuromyelitis optica with mycophenolate mofetil: retrospective analysis of 24 patients. Arch. Neurol. 66, 1128–1133.
Jacob, A, Weinshenker, BG, Violich, I, et al., 2008. Treatment of neuromyelitis optica with rituximab: retrospective analysis of 25 patients. Arch. Neurol. 65, 1443–1448.
Jarius, S, Aboul-Enein, F, Waters, P, et al., 2008. Antibody to aquaporin-4 in the long-term course of neuromyelitis optica. Brain 131 (Pt 11), 3072–3080.
Jarius, S, Franciotta, D, Paul, F, et al., 2010. Cerebrospinal fluid antibodies to aquaporin-4 in neuromyelitis optica and related disorders: frequency, origin, and diagnostic relevance. J. Neuroinflammation. 7, 52.
Jarius, S, Paul, F, Aktas, O, et al., 2018. MOG encephalomyelitis: international recommendations on diagnosis and antibody testing. J. Neuroinflammation. 15 (1), 134.
Jarius, S, Paul, F, Franciotta, D, et al., 2011. Cerebrospinal fluid findings in aquaporin-4 antibody positive neuromyelitis optica: results from 211 lumbar punctures. J. Neurol. Sci. 306 (1-2), 82–90 Jul 15.
Jarius, S, Ruprecht, K, Wildemann, B, et al., 2012. Contrasting disease patterns in seropositive and seronegative neuromyelitis optica: a multicentre study of 175 patients. J. Neuroinflammation. 9, 14.
Jarius, S, Wildemann, B, 2013. Aquaporin-4 antibodies (NMO-IgG) as a serological marker of neuromyelitis optica: a critical review of the literature. Brain Pathol. 23, 661–683.
Jarius, S., et al., 2016. MOG-IgG in NMO and related disorders: a multicenter study of 50 patients. Part 1: frequency, syndrome specificity, influence of disease activity, long-term course, association with AQP4-IgG, and origin. J. Neuroinflammation. 13, 279.
Jeong, IH, Park, B, Kim, SH, Hyun, JW, Joo, J, Kim, HJ, 2016. Comparative analysis of treatment outcomes in patients with neuromyelitis optica spectrum disorder using multifaceted endpoints. Mult. Scler. 22 (3), 329–339.
Juryńczyk, M, Jacob, A, Fujihara, K, Palace, J, 2019. Myelin oligodendrocyte glycoprotein (MOG) antibody-associated disease: practical considerations. Pract Neurol 19 (3), 187–195.
Kawachi, I, Lassmann, H., 2017. Neurodegeneration in multiple sclerosis and neuromyelitis optica. J. Neurol. Neurosurg. Psychiatry 88 (2), 137–145.
Kim, HJ, Paul, F, Lana-Peixoto, MA, et al., 2015. MRI characteristics of neuromyelitis optica spectrum disorder: an international update. Neurology 84 (11), 1165–1173.
Kim, S.H., Kim, W., Li, X.F., et al., 2011. Repeated treatment with rituximab based on the assessment of peripheral circulating memory B cells in patients with relapsing neuromyelitis optica over 2 years. Arch. Neurol. 68, 1412–1420.
Kim, SH, Hyun, JW, Joung, A, Lee, SH, Kim, HJ, 2016. Occurrence of asymptomatic acute neuromyelitis optica spectrum disorder-typical brain lesions during an attack of optic neuritis or myelitis. PLoS ONE 11 (12), e0167783.
Kim, SH, Hyun, JW, Joung, A, Park, EY, Joo, J, Kim, HJ, 2017. Predictors of response to first-line immunosuppressive therapy in neuromyelitis optica spectrum disorders. Mult. Scler. 23 (14), 1902–1908.
Kim, SH, Hyun, JW, Kim, HJ, 2019. Individualized B cell-targeting therapy for neuromyelitis optica spectrum disorder. Neurochem. Int. 130, 104347 Nov;.
Kim, SH, Jeong, IH, Hyun, JW, et al., 2015. Treatment outcomes with rituximab in 100 patients with neuromyelitis optica: influence of FCGR3A polymorphisms on the therapeutic response to rituximab. JAMA Neurol. 72, 989–995.
Kim, SM, Kim, SJ, Lee, HJ, Kuroda, H, Palace, J, Fujihara, K, 2017. Differential diagnosis of neuromyelitis optica spectrum disorders. Ther. Adv. Neurol. Disord. 10 (7), 265–289.
Kim, SM, Park, J, Kim, SH, et al., 2013. Factors associated with the time to next attack in neuromyelitis optica: accelerated failure time models with random effects. PLoS ONE 8 (12), e82325.
Kim, SM, Waters, P, Vincent, A, et al., 2011. Cerebrospinal fluid/serum gradient of IgG is associated with disability at acute attacks of neuromyelitis optica. J. Neurol. 258, 2176–2180.
Kim, W, Kim, SH, Nakashima, I, et al., 2012. Influence of pregnancy on neuromyelitis optica spectrum disorder. Neurology 78, 1264–1267.
Kim, YJ, Jung, SW, Kim, Y, et al., 2012. Detection of anti-aquaporin-4 antibodies in neuromyelitis optica: comparison of tissue-based and cell-based indirect immunofluorescence assays and ELISA. J. Clin. Lab. Anal. 26, 184–189.
Kimbrough, DJ, Fujihara, K, Jacob, A, et al., 2012. Treatment of neuromyelitis optica: review and recommendations. Mult. Scler. Relat. Disord. 1 (4), 180–187 Oct.
Kitley, J, Leite, MI, 2012. Nakashima I et al Prognostic factors and disease course in aquaporin-4 antibody positive patients with neuromyelitis optica spectrum disorder from the United Kingdom and Japan. Brain 135, 1834–1849.
Klawiter, EC, Bove, R, Elsone, L, Alvarez, E, Borisow, N, Cortez, M, et al., 2017. High risk of postpartum relapses in neuromyelitis optica spectrum disorder. Neurology 89, 2238–2244.
Kleiter, I, Gahlen, A, Borisow, N, Fischer, K, Wernecke, KD, Hellwig, K, et al., 2018. Apheresis therapies for NMOSD attacks: a retrospective study of 207 therapeutic interventions. Neurol. Neuroimmunol. Neuroinflamm.. 5, e504.
Kleiter, I, Gahlen, A, Borisow, N, Fischer, K, Wernecke, KD, Wegner, B, et al., 2016. Neuromyelitis optica: evaluation of 871 attacks and 1,153 treatment courses. Ann. Neurol. 79, 206–216.
Lana-Peixoto, MA, Pedrosa, D, Talim, N, Amaral, JMSS, Horta, A, Kleinpaul, R, 2018. Neuromyelitis optica spectrum disorder associated with dengue virus infection. J. Neuroimmunol. 318, 53–55 May 15.
Lana-Peixoto, MA, Talim, N., 2019. Neuromyelitis optica spectrum disorder and anti-MOG syndromes. Biomedicines 7 (2).
Lennon, VA, Kryzer, TJ, Pittock, SJ, et al., 2005. IgG marker of optic-spinal multiple sclerosis binds to the aquaporin-4 water channel. J. Exp. Med. 202 (4), 473–477.
Lennon, VA, Wingerchuk, DM, Kryzer, TJ, et al., 2004. A serum autoantibody marker of neuromyelitis optica: distinction from multiple sclerosis. Lancet 364 (9451), 2106–2112.
Li, GH, Ning, ZJ, Liu, YM, Li, XH, 2017. Neurological manifestations of dengue infection. Front. Cell Infect. Microbiol. 7, 449.
Lim, YM, Pyun, SY, Kang, BH, Kim, J, Kim, KK, 2013. Factors associated with the effectiveness of plasma exchange for the treatment of NMO-IgG-positive neuromyelitis optica spectrum disorders. Mult. Scler. 19 (9), 1216–1218 Aug;.
Liu, J, Zhang, Q, Lian, Z, Chen, H, Shi, Z, Feng, H, Miao, X, Du, Q, Zhou, H, 2017. Painful tonic spasm in neuromyelitis optica spectrum disorders: prevalence, clinical implications and treatment options. Mult. Scler. Relat. Disord. 17, 99–102.
Lotan, I, Charlson, RW, Ryerson, LZ, Levy, M, Kister, I, 2019. Effectiveness of subcutaneous tocilizumab in neuromyelitis optica spectrum disorders. Mult. Scler. Relat. Disord. 39, 101920 Dec 30.
Magaña, SM, Keegan, BM, Weinshenker, BG, Erickson, BJ, Pittock, SJ, Lennon, VA, Rodriguez, M, Thomsen, K, Weigand, S, Mandrekar, J, Linbo, L, Lucchinetti, CF, 2011. Beneficial plasma exchange response in central nervous system inflammatory demyelination. Arch. Neurol. 68 (7), 870–878 Jul;.
Majed, Masoud, Fryer, James P., McKeon, Andrew, et al., 2016. Clinical utility of testing AQP4-IgG in CSF: guidance for physicians. Neurol. Neuroimmunol. Neuroinflamm. 3 (3), e231 Jun.
Mandler, RN, Ahmed, W, Dencoff, JE, 1998. Devic's neuromyelitis optica: a prospective study of seven patients treated with prednisone and azathioprine. Neurology 51, 1219–1220.
Mao-Draayer, Y, Thiel, S, Mills, EA, Chitnis, T, Fabian, M, Katz Sand, I, Leite, MI, Jarius, S, Hellwig, K, 2020. Neuromyelitis optica spectrum disorders and pregnancy: therapeutic considerations. Nat Rev Neurol Feb 20.
Marcinnò, A, Marnetto, F, Valentino, P, et al., 2018. Rituximab-induced hypogammaglobulinemia in patients with neuromyelitis optica spectrum disorders. Neurol. Neuroimmunol. Neuroinflamm. 5 (6), e498.
Marignier, R, Bernard-Valnet, R, Giraudon, P, et al., 2013. Aquaporin-4 antibody-negative neuromyelitis optica: distinct assay sensitivity dependent entity. Neurology 80, 2194–2200.
Mariotto, S, Ferrari, S, Monaco, S, et al., 2017. Clinical spectrum and IgG subclass analysis of anti-myelin oligodendrocyte glycoprotein antibody associated syndromes: a multicenter study. J. Neurol. 264, 2420–2430.
Matiello, M, Lennon, VA, Jacob, A, et al., 2008. NMO-IgG predicts the outcome of recurrent optic neuritis. Neurology 70, 2197–2200.
Matthews, LA, Marasco, R, Jenkinson, M, et al., 2013. Distinction of seropositive NMO spectrum disorder and MS brain lesion distribution. Neurology 80, 1330–1337.
McCreary, M, Mealy, MA, Wingerchuk, DM, et al., 2018. Updated diagnostic criteria for neuromyelitis optica spectrum disorder: similar outcomes of previously separate cohorts. Mult. Scler. J. Exp. Transl. Clin. 4 (4), 2055217318815925 Dec 6.
McKinney, AM, Lohman, BD, Sarikaya, B, Benson, M, Lee, MS, Benson, MT, 2013. Accuracy of routine fat-suppressed FLAIR and diffusion-weighted images in detecting clinically evident acute optic neuritis. Acta Radiol. 54 (4), 455–461.
Mealy, MA, Kessler, RA, Rimler, Z, et al., 2018. Mortality in neuromyelitis optica is strongly associated with African ancestry. Neurol. Neuroimmunol. Neuroinflamm.. 5 (4), e468 Published 2018 Jun 7.
Mealy, MA, Wingerchuk, DM, Palace, J, et al., 2014. Comparison of relapse and treatment failure rates among patients with neuromyelitis optica: multicenter study of treatment efficacy. JAMA Neurol. 71, 324–330.
Mok, CC, To, CH, Mak, A, Poon, WL, 2008. Immunoablative cyclophosphamide for refractory lupus-related neuromyelitis optica. J. Rheumatol. 35 (1), 172–174.
Montcuquet, A, Collongues, N, Papeix, C, Zephir, H, Audoin, B, Laplaud, D, et al., 2017. Effectiveness of mycophenolate mofetil as first-line therapy in AQP4-IgG, MOG-IgG, and seronegative neuromyelitis optica spectrum disorders. Mult. Scler. 23 (10), 1377–1384.
Mutch, K, Methley, A, Moore, P, Jacob, A, 2014. Life on hold: the experience of living with neuromyelitis optica. Disabil. Rehabil. 36 (13), 1100–1107.
Nagaishi, A, Takagi, M, Umemura, A, et al., 2011. Clinical features of neuromyelitis optica in a large Japanese cohort: comparison between phenotypes. J. Neurol. Neurosurg. Psychiatry 82, 1360–1364.
Nakashima, I, Takahashi, T, Cree, BA, et al., 2011. Transient increases in anti-aquaporin-4 antibody titers following rituximab treatment in neuromyelitis optica, in association with elevated serum BAFF levels. J. Clin. Neurosci. 18 (7), 997–998.
Narayan, R, Simpson, A, Fritsche, K, et al., 2018. MOG antibody disease: a review of MOG antibody seropositive neuromyelitis optica spectrum disorder. Mult. Scler. Relat. Disord. 25, 66–72.
Nikoo, Z, Badihian, S, Shaygannejad, V, Asgari, N, Ashtari, F, 2017. Comparison of the efficacy of azathioprine and rituximab in neuromyelitis optica spectrum disorder: a randomized clinical trial. J. Neurol. 264, 2003–2009.
Nishimura, H, Enokida, H, Sakamoto, T, et al., 2018 Sep Sep. Immunoadsorption plasmapheresis treatment for the recurrent exacerbation of neuromyelitis optica spectrum disorder with a fluctuating anti-aquaporin-4 antibody level. J. Artif. Organs 21 (3), 378–382.
Nour, MM, Nakashima, I, Coutinho, E, et al., 2016. Pregnancy outcomes in aquaporin-4-positive neuromyelitis optica spectrum disorder. Neurology 86, 79–87.
Oertel, FC, Zimmermann, H, Paul, F, Brandt, AU, 2017. Optical coherence tomography in neuromyelitis optica spectrum disorders: potential advantages for individualized monitoring of progression and therapy. EPMA J. 9 (1), 21–33.
Palace, J, Leite, MI, Jacob, A, 2012. A practical guide to the treatment of neuromyelitis optica. Pract. Neurol. 12 (4), 209–214 Aug.
Palace, J, Lin, DY, Zeng, D, et al., 2019. Outcome prediction models in AQP4-IgG positive neuromyelitis optica spectrum disorders. Brain 142, 1310–1323.
Papais-Alvarenga, RM, Carellos, SC, Alvarenga, MP, Holander, C, Bichara, RP, Thuler, LC, 2008. Clinical course of optic neuritis in patients with relapsing neuromyelitis optica. Arch. Ophthalmol. 126 (1), 12–16 Jan.

Papais-Alvarenga, RM, Neri, VC, de Araújo, E, Araújo, ACR, et al., 2018. Lower frequency of antibodies to MOG in Brazilian patients with demyelinating diseases: an ethnicity influence? Mult. Scler. Relat. Disord. 25, 87–94.
Papais-Alvarenga, RM, Vasconcelos, CC, Carra, A, et al., 2015. Central nervous system idiopathic inflammatory demyelinating disorders in South Americans: a descriptive, multicenter, cross-sectional study. PLoS ONE 10 (7), e0127757 Jul 29.
Papais-Alvarenga, RM, Vasconcelos, CC, Carra, A, et al., 2015. Central nervous system idiopathic inflammatory demyelinating disorders in South Americans: a descriptive, multicenter, cross-sectional study. PLoS ONE 10 (7), e0127757.
Pellkofer, HL, Krumbholz, M, Berthele, A, et al., 2011. Long-term follow-up of patients with neuromyelitis optica after repeated therapy with rituximab. Neurology 76 (15), 1310–1315.
Perumal, J.S., Kister, I., Howard, J., Herbert, J., 2015. Disease exacerbation after rituximab induction in neuromyelitis optica. Neurol. Neuroimmunol. Neuroinflamm. 2, e61.
Petzold, A, Wattjes, MP, Costello, F, et al., 2014. The investigation of acute optic neuritis: a review and proposed protocol [published correction appears in Nat Rev Neurol. 2014 Aug;10(8):i]. Nat Rev Neurol. 10 (8), 447–458.
Pittock, SJ, Berthele, A, Fujihara, K, et al., 2019. Eculizumab in aquaporin-4-positive neuromyelitis optica spectrum disorder. N. Engl. J. Med. 381 (7), 614–625 Aug 15.
Pittock, SJ, Lennon, VA, de Seze, J, et al., 2008. Neuromyelitis optica and non-organ-specific autoimmunity. Arch. Neurol. 65 (1), 78–83.
Pittock, SJ, Lennon, VA, Krecke, K, Wingerchuk, DM, Lucchinetti, CF, Weinshenker, BG, 2006. Brain abnormalities in neuromyelitis optica. Arch. Neurol. 63, 390–396.
Prain, Kerri, Woodhall, Mark, Vincent, Angela, The Australian and New Zealand NMO Collaboration,Brilot, Fabienne, Waters, Patrick, Broadley, Simon A., et al., The Australian and New Zealand NMO Collaboration, 2019. AQP4 antibody assay sensitivity comparison in the era of the 2015 diagnostic criteria for NMOSD. Front. Neurol. 10, 1028.
Qiu, W, Kermode, AG, Li, R, et al., 2015. Azathioprine plus corticosteroid treatment in Chinese patients with neuromyelitis optica. J. Clin. Neurosci. 22, 1178–1182.
Rand Corporation. The RAND/UCLA appropriateness method user's manual. Santa Monica: RAND; 2001. Development of Good Practice Guidelines. "Formal Consensus" Method. December 2010, updated March2015.https://www.hassante.fr/portail/upload/docs/application/pdf/201803/good_practice_guidelines_fc_method.pdf.
Reindl, M, Schanda, K, Woodhall, M, et al., 2020. International multicenter examination of MOG antibody assays. Neurol. Neuroimmunol. Neuroinflamm. 7 (2) Feb 5.
Reindl, M, Waters, P., 2019. Myelin oligodendrocyte glycoprotein antibodies in neurological disease. Nat. Rev. Neurol. 15, 89–102.
Ringelstein, M, Ayzenberg, I, Harmel, J, et al., 2015. Long-term therapy with interleukin 6 receptor blockade in highly active neuromyelitis optica spectrum disorder. JAMA Neurol. 72, 756–763.
Rivas-Alonso, V, Flores-Rivera, JDJ, Rito-García, Y, et al., 2018. Neuromyelitis optica (NMO IgG+) and genetic susceptibility, potential ethnic influences. Cent. Nerv. Syst. Agents Med. Chem. 18 (1), 4–7 Jan 26;.
Rivera, JF, Kurtzke, JF, Booth, VJ, Corona, T, 2008. Characteristics of devic's disease (neuromyelitis optica) in Mexico. J Neurol. 255, 710–715 2.
Salvador, NRS, Brito, MNG, Alvarenga, MP, Alvarenga, RMP, 2019. Neuromyelitis optica and pregnancy-puerperal cycle. Mult. Scler. Relat. Disord. 34, 59–62 Sep.
Santori, G, Fontana, I, Valente, R, Ghirelli, R, Valente, U, 2008. Application of the RAND/UCLA appropriateness method to evaluate an information system for kidney/pancreas transplantation in adult recipients. Transplant. Proc. 40 (6), 2021–2023.
Sati, P, Oh, J, Constable, RT, et al., 2016. The central vein sign and its clinical evaluation for the diagnosis of multiple sclerosis: a consensus statement from the North American Imaging in Multiple Sclerosis Cooperative. Nat. Rev. Neurol. 12 (12), 714–722.
Sato, DK, Callegaro, D, Lana-Peixoto, MA, et al., 2014b. Distinction between MOG antibody-positive and AQP4 antibody-positive NMO spectrum disorders. Neurology 82 (6), 474–481.
Sato, DK, Callegaro, D, Lana-Peixoto, MA, et al., 2014a. Seronegative neuromyelitis optica spectrum—the challenges on disease definition and pathogenesis. Arq. Neuropsiquiatr. 72 (6), 445–450.
Sellner, J, Boggild, M, Clanet, M, Hintzen, RQ, Illes, Z, Montalban, X, Du Pasquier, RA, Polman, CH, Sorensen, PS, Hemmer, B, 2010. EFNS guidelines on diagnosis and management of neuromyelitis optica. Eur. J. Neurol. 17 (8), 1019–1032.
Seok, JM, Cho, EB, Lee, HL, et al., 2016. Clinical characteristics of disabling attacks at onset in patients with neuromyelitis optica spectrum disorder. J. Neurol. Sci. 368, 209–213 Sep 15.
Seze, Jerome De, Weinshenker, Brian G., Terada, Yusuke, 2020. Efficacy and safety of satralizumab for relapse prevention in neuromyelitis optica spectrum disorder: a pooled analysis from two phase 3 clinical trials. Mult. Scler. 37, 101592. https://doi.org/10.1016/j.msard.2019.11.067. January 01.
Shaygannejad, V, Fayyazi, E, Badihian, S, et al., 2019. Long-term tolerability, safety and efficacy of rituximab in neuromyelitis optica spectrum disorder: a prospective study. J. Neurol. 266 (3), 642–650.
Shi, Z, Du, Q, Chen, H, et al., 2019. Effects of immunotherapies and prognostic predictors in neuromyelitis optica spectrum disorder: a prospective cohort study. J. Neurol. https://doi.org/10.1007/s00415-019-09649-7. Nov 27[Epub ahead of print].
Shimizu, Y, Fujihara, K, Ohashi, T, Nakashima, I, Yokoyama, K, Ikeguch, R, et al., 2016. Pregnancy-related relapse risk factors in women with anti-AQP4 antibody positivity and neuromyelitis optica spectrum disorder. Mult. Scler. 22, 1413–1420.
Shosha, E, Pittock, SJ, Flanagan, E, Weinshenker, BG, 2017. Neuromyelitis optica spectrum disorders and pregnancy: interactions and management. Mult. Scler. 23 (14), 1808–1817.
Silveira, F, Pappolla, A, Sánchez, F, et al., 2020. Brain magnetic resonance imaging features in multiple sclerosis and neuromyelitis optica spectrum disorders patients with or without aquaporin-4 antibody in a Latin American population. Mult. Scler. Relat. Disord. 42, 102049.
Sinnecker, T, Clarke, MA, Meier, D, et al., 2019. Evaluation of the central vein sign as a diagnostic imaging biomarker in multiple sclerosis [published online ahead of print, 2019 Aug 19]. JAMA Neurol. 76 (12). https://doi.org/10.1001/jamaneurol.2019.2478.
Songthammawat, T, Srisupa-Olan, T, Siritho, S, et al., 2019. A pilot study comparing treatments for severe attacks of neuromyelitis optica spectrum disorders: intravenous methylprednisolone (IVMP) with add-on plasma exchange (PLEX) versus simultaneous ivmp and PLEX. Mult. Scler. Relat. Disord. 38, 101506 Nov 6.
Sotirchos, ES, Filippatou, A, Fitzgerald, KC, et al., 2019. Aquaporin-4 IgG seropositivity is associated with worse visual outcomes after optic neuritis than MOG-IgG seropositivity and multiple sclerosis, independent of macular ganglion cell layer thinning [published online ahead of print, 2019 Jul 31]. Mult. Scler 1352458519864928.
Soto de Castillo, I, Molina, O, Soto, A, et al., 2019. Neuromyelitis optica spectrum disorders: epidemiologic study in Venezuela. In: Presented at the 11th International NMO Roundtable Conference. Los Angeles.
Srikajon, J, Siritho, S, Ngamsombat, C, Prayoonwiwat, N, Chirapapaisan, N, Siriraj Neuroimmunology Research Group, 2018. Differences in clinical features between optic neuritis in neuromyelitis optica spectrum disorders and in multiple sclerosis. Mult. Scler. J. Exp. Transl. Clin. 4 (3), 2055217318791196 Aug 11;.
Stellmann, JP, Krumbholz, M, Friede, T, Gahlen, A, Borisow, N, Fischer, K, et al., 2017. Immunotherapies in neuromyelitis optica spectrum disorder: efficacy and predictors of response. J. Neurol. Neurosurg. Psychiatry 88, 639–647.
Stiebel-Kalish, H, Hellmann, MA, Mimouni, M, et al., 2019. Does time equal vision in the acute treatment of a cohort of AQP4 and MOG optic neuritis? Neurol. Neuroimmunol. Neuroinflamm.. 6 (4), e572 Published 2019 May 21.
Takahashi, T, Fujihara, K, Nakashima, I, et al., 2007. Anti-aquaporin-4 antibody is involved in the pathogenesis of NMO: a study on antibody titre. Brain 130, 1235–1243.
Thompson, AJ, Banwell, BL, Barkhof, F, et al., 2018. Diagnosis of multiple sclerosis: 2017 revisions of the McDonald criteria. Lancet Neurol. 17 (2), 162–173.
Torres, J, Pruitt, A, Balcer, L, et al., 2015. Analysis of the treatment of neuromyelitis optica. J. Neurol. Sci. 351, 31–35.
Trebst, C, Jarius, S, Berthele, A, Neuromyelitis Optica Study Group (NEMOS), et al., 2014. Update on the diagnosis and treatment of neuromyelitis optica: recommendations of the Neuromyelitis Optica Study Group (NEMOS). J. Neurol. 261 (1), 1–16.
von Glehn, F, Jarius, S, Penalva de Oliveira, AC, et al., 2012. Aquaporin-4 antibodies are not related to HTLV-1 associated myelopathy. PLoS ONE 7 (7), e39372.
Watanabe, S, Misu, T, Miyazawa, I, Nakashima, I, Shiga, Y, Fujihara, K, et al., 2007. Low-dose corticosteroids reduce relapses in neuromyelitis optica: a retrospective analysis. Mult. Scler. 13 (8), 968–974.
Waters, P, McKeon, A, Leite, M, et al., 2012. Serologic diagnosis of NMO: a multicenter comparison of aquaporin-4-IgG assays. Neurology 78, 665–671.
Waters, P, Woodhall, M, O'Connor, KC, et al., 2015. MOG cell-based assay detects non-MS patients with inflammatory neurologic disease. Neurol. Neuroimmunol. Neuroinflamm. 2, e89.
Waters, PJ, Pittock, SJ, Bennett, JL, Jarius, S, Weinshenker, BG, Wingerchuk, DM, 2014. Evaluation of aquaporin-4 antibody assays. Clin. Exp. Neuroimmunol. 5 (3), 290–303.
Weinshenker, BG, O'Brien, PC, Petterson, TM, Noseworthy, JH, Lucchinetti, CF, Dodick, DW, et al., 1999. A randomized trial of plasma exchange in acute central nervous system inflammatory demyelinating disease. Ann. Neurol. 46 (6), 878–886.
Weinshenker, BG, Wingerchuk, DM, Vukusic, S, et al., 2006. Neuromyelitis optica IgG predicts relapse after longitudinally extensive transverse myelitis. Ann. Neurol. 59, 566–569.
Weinshenker, BG, Wingerchuk, DM., 2017. Neuromyelitis spectrum disorders. Mayo Clin. Proc. 92 (4), 663–679.
Weinstock-Guttman, B, Ramanathan, M, Lincoff, N, Napoli, SQ, Sharma, J, Feichter, J, et al., 2006. Study of mitoxantrone for the treatment of recurrent neuromyelitis optica (Devic disease). Arch. Neurol. 63 (7), 957–963.
Whittam, D, Wilson, M, Hamid, S, Keir, G, Bhojak, M, Jacob, A, 2017. What's new in neuromyelitis optica? A short review for the clinical neurologist. J. Neurol. 264 (11), 2330–2344.
Wingerchuk, D, Lennon, V, Lucchinetti, C, et al., 2007. The spectrum of neuromyelitis optica. Lancet Neurol. 6, 805–815.
Wingerchuk, D, Weinshenker, B, 2012. The emerging relationship between neuromyelitis optica and systemic rheumatologic autoimmune disease. Mult. Scler. 18, 5–10.
Wingerchuk, D.M., Pittock, S.J., Lucchinetti, C.F., et al., 2007. A secondary progressive clinical course is uncommon in neuromyelitis optica. Neurology 68, 603–605.
Wingerchuk, D.M., Weinshenker, B.G.Neuromyelitis optica:, 2003. clinical predictors of a relapsing course and survival. Neurology 60, 848–853.
Wingerchuk, DM, Banwell, B, Bennett, JL, International Panel for NMO Diagnosis, et al., 2015. International consensus diagnostic criteria for neuromyelitis optica spectrum disorders. Neurology 85 (2), 177–189.
Wingerchuk, DM, Hogancamp, WF, O'Brien, PC, et al., 1999. The clinical course of neuromyelitis optica (Devic's syndrome). Neurology 53, 1107–1114.
Wingerchuk, DM, Lennon, VA, Pittock, SJ, Lucchinetti, CF, Weinshenker, BG, 2006. Revised diagnostic criteria for neuromyelitis optica. Neurology 66 (10), 1485–1489.
Yamamura, T, Kleiter, I, Fujihara, K, Palace, J, Greenberg, B, Zakrzewska-Pniewska, B, Patti, F, Tsai, CP, Saiz, A, Yamazaki, H, Kawata, Y, Wright, P, De Seze, J, 2019. Trial of satralizumab in neuromyelitis optica spectrum disorder. N. Engl. J. Med. 381 (22), 2114–2124 Nov 28;.
Yang, Y, Wang, CJ, Wang, BJ, Zeng, ZL, Guo, SG, 2018. Comparison of efficacy and tolerability of azathioprine, mycophenolate mofetil, and lower dosages of rituximab among patients with neuromyelitis optica spectrum disorder. J. Neurol. Sci. 385, 192–197.

Zamvil, SS, Slavin, AJ., 2015. Does MOG Ig-positive AQP4-seronegative opticospinal inflammatory disease justify a diagnosis of NMO spectrum disorder? Neurol. Neuroimmunol. Neuroinflamm 2 (1), e62.
Zatjirua, V, Butler, J, Carr, J, et al., 2011. Neuromyelitis optica and pulmonary tuberculosis: a case-control study. Int. J. Tuberc. Lung Dis. 15 (12), 1675–1680.
Zephir, H, Bernard-Valnet, R, Lebrun, C, et al., 2015. Rituximab as first-line therapy in neuromyelitis optica: efficiency and tolerability. J. Neurol. 262, 2329–2335.
Zhang, C, Zhang, M, Qiu, W, et al., 2020. Safety and efficacy of tocilizumab versus azathioprine in highly relapsing neuromyelitis optica spectrum disorder (TANGO): an open-label, multicentre, randomised, phase 2 trial. Lancet Neurol. 19 (5), 391–401.