CNS Drugs
https://doi.org/10.1007/s40263-020-00704-w

REVIEW ARTICLE

Anti-CD20 Monoclonal Antibodies for Relapsing and Progressive Multiple Sclerosis

Finn Sellebjerg[1] · Morten Blinkenberg[1] · Per Soelberg Sorensen[1]

© Springer Nature Switzerland AG 2020

Abstract

Multiple sclerosis (MS) was previously thought to be a T-cell-mediated, demyelinating disease of the central nervous system. Disease-modifying therapies targeting T cells have, indeed, shown remarkable efficacy in patients with relapsing-remitting MS. However, these therapies do also target B cells, and a B-cell-depleting monoclonal antibody (ocrelizumab) has recently been approved for MS therapy and is efficacious not only in relapsing forms of MS but also in some patients with primary progressive MS. This suggests that B cells may play a more important role in the pathogenesis of MS than previously appreciated. We review the potential roles of B cells, which are the precursors of antibody-secreting plasma cells in the pathogenesis of MS. Furthermore, we provide an overview of the characteristics and clinical data for the four monoclonal antibodies (ocrelizumab, ofatumumab, rituximab, and ublituximab) that have been approved, are currently been used off-label or are being investigated as treatments for MS. These antibodies all target the cluster of differentiation (CD)-20 molecule and bind to distinct or overlapping epitopes on B cells and a subset of T cells that express CD20. This leads to B-cell depletion and, possibly, to depletion of CD20-positive T cells. The net result is strong suppression of clinical and radiological disease activity as well as slowing of the development of persisting neurological impairment.

Key Points

Anti-cluster of differentiation (CD)-20 monoclonal antibodies induce profound depletion of circulating B lymphocytes after systemic administration.

In relapsing-remitting multiple sclerosis (MS), the B-cell depletion is associated with a reduction in the occurrence of relapses and in disability worsening, and the effect on disease activity in magnetic resonance imaging (MRI) is remarkably pronounced.

The short-term safety profile in phase III studies appears favorable, but long-term follow-up studies will be needed to assess the benefit/risk profile of anti-CD20 monoclonal antibodies.

✉ Per Soelberg Sorensen
pss@rh.dk

[1] Danish Multiple Sclerosis Clinic, Department of Neurology 2082, University of Copenhagen, Rigshospitalet, 9 Blegdamsvej, 2100 Copenhagen, Denmark

1 Introduction

Multiple sclerosis (MS) is an immune-mediated disease of the central nervous system (CNS) [1]. In most patients, MS initially runs a relapsing-remitting (RR) disease course with episodes of new or worsening symptoms developing over a few days, peaking for a few weeks, and remitting partially or completely after several weeks to a few months [2]. In this disease phase, a close relationship exists between relapses and the occurrence of new lesions on magnetic resonance imaging (MRI) [3]. There is compelling evidence that disease activity in relapsing-remitting MS (RRMS), i.e. relapses and MRI activity, is immune mediated. Pulsed immune reconstitution therapy with the monoclonal anti-cluster of differentiation (CD)-52 antibody alemtuzumab and the lymphocyte-selective cytotoxic drug cladribine or high-dose chemotherapy with autologous hematopoietic stem cell support can lead to long-lasting activity-free remission in RRMS [4]. Furthermore, treatment with the anti-very late antigen-4 antibody natalizumab, inhibiting the migration of lymphocytes across the blood–brain barrier, is highly efficacious in suppressing disease activity in MS [5]. It has been generally assumed that the efficacy of these therapies in RRMS is explained by inhibitory effects on pathogenic,

Published online: 28 January 2020

autoreactive T cells, but these therapies also target B cells [6]. Several placebo-controlled clinical trials have, indeed, shown that treatment with anti-CD20 monoclonal antibodies targeting B cells is highly efficacious in RRMS [7–11].

Some 10–15% of patients have primary progressive MS (PPMS), with more gradual onset of disease with symptoms evolving over several years [2]. The onset of PPMS usually occurs in patients who, on average, are about 10 years older than patients with RRMS onset. A gradually progressive disease course comparable to PPMS, termed secondary progressive MS (SPMS), follows in many patients 20–30 years after an initially RR disease [2]. Anti-CD20 antibody therapy has also shown efficacy in slowing progression in PPMS, whereas controlled studies in SPMS are still lacking [12, 13].

Taken together, accumulating data indicate a pivotal role of B cells in the pathogenesis of MS. We discuss the role of B cells in the immunopathogenesis of MS, review mechanisms of action of anti-CD20 antibodies, and review data on the efficacy and safety of the anti-CD20 antibodies rituximab, ocrelizumab, ofatumumab, and ublituximab in MS.

2 Immunology and Immunopathology of Multiple Sclerosis

MS is thought to result from a dysregulated immune response in genetically susceptible individuals, which results in demyelination and axonal and neuronal loss in the CNS [1, 14]. B cells are the precursors of plasma cells, which—upon activation—proliferate and differentiate into immunoglobulin-secreting plasmablasts and plasma cells. It is well-established that aberrant B-cell responses in the CNS are prominent in MS. Intrathecally synthesized immunoglobulin G (IgG) in the form of IgG oligoclonal bands in cerebrospinal fluid (CSF) is a hallmark of the disease and are included in the most recent McDonald diagnostic criteria for MS [15, 16]. Oligoclonal bands are highly stable over time in patients with established MS, and different bands in an individual patient may be clonally related [17, 18]. The B cells present in the CSF are not necessarily clonally related to antibody-producing plasma cells in the same patient [19], but clonally related B cells have been identified in blood and CSF and may undergo clonal expansion and diversification either in the periphery of or within the CNS [17, 20]. Interestingly, maturation of the B-cell response seems to occur to a large extent in the cervical lymph nodes, which provides a plausible explanation for why systemic depletion of B cells or inhibition of their recruitment to the CNS is efficacious in MS [21].

Antibody reactivity to a variety of autoantigens has been reported in MS [6], but the antibody specificity of the IgG oligoclonal bands in MS remains uncertain, and no definite autoantigenic target of the intrathecally synthesized IgG has yet been identified in MS [16]. Nevertheless, histopathology studies have demonstrated deposition of immunoglobulins and complement factors on myelin debris in active MS lesions [22], and complement activation products are present in CSF from patients with MS [23, 24]. Interestingly, histopathology studies suggest that only a subset of patients with MS show evidence of antibody- and complement-mediated pathophysiology and that such patients are more likely to respond to treatment with plasma exchange [25, 26]. These findings, together with studies showing that approximately 30% of patients with MS have circulating autoantibodies with complement-dependent, demyelinating activity in vitro, support the notion that at least a subgroup of patients with MS have pathogenic, circulating autoantibodies [27].

Although these data support a pathogenic role for autoantibodies in a subgroup of patients with MS, B cells are thought to play more important roles than serving as the precursors of autoantibody-secreting plasma cells [6]. Indeed, in the animal model experimental autoimmune encephalomyelitis (EAE), the pathogenic role of the B cell does not depend on the capacity to secrete autoantibodies. Thus, B cells are highly potent antigen-presenting cells, especially for protein antigens for which they express specific surface immunoglobulin receptors [28]. The role of B cells in the stimulation of pathogenic T-cell responses in MS was recently highlighted in studies suggesting that memory B cells from patients with MS stimulate autoreactive T cells with brain-homing properties. These T cells appear to target a novel autoantigen co-expressed in B cells and the CNS [29]. This T-cell response was reduced after in vivo B-cell depletion with the anti-CD20 antibody rituximab.

In addition to serving as antigen-presenting cells, B cells secreting proinflammatory cytokines such as interleukin (IL)-6 contribute to the pathogenesis of EAE [28, 30]. B cells from patients with MS show increased expression of the transcription factor nuclear factor κB (NFκB) after activation via the CD40 molecule [31]. NFκB is a key transcription factor in the induction of proinflammatory responses, and B cells from patients with MS produce increased levels of many proinflammatory cytokines [32–35]. IL-15, granulocyte-monocyte colony stimulating factor, lymphotoxin-α, and tumor necrosis factor-α produced by B cells were found to contribute to the activation of proinflammatory T helper type 1 (Th1) and Th17 cells, cytotoxic CD8 T cells, and myeloid cells [32–34]. These findings support the notion that therapy with B-cell-depleting antibodies may target proinflammatory B-cell cytokine responses involved in the induction of systemic, pathogenic immune responses in MS.

Subsets of B cells termed regulatory B cells (B_{reg} cells) produce immunoregulatory cytokines, e.g., IL-10 and IL35, and B_{reg} cells are known to have regulatory potential in EAE [36, 37]. Although studies of B-cell production of immunoregulatory cytokines in MS have yielded conflicting results [32, 35, 38–40], it is clear that anti-CD20 antibody therapies will equally deplete

proinflammatory B cells and B_{reg} cells. Depletion of B_{reg} cells may, indeed, provide an explanation for the unexpected observation of increased monocyte activation in patients treated with rituximab [41].

In addition to involvement in the development of systemic immune responses, B cells are also thought to have pathogenic effects in the CNS. B cells infiltrate the brain parenchyma in MS, and B-cell infiltration is a prominent feature in some patients with MS [42, 43]. Increased B-cell activation has, indeed, been observed even in studies of CSF cells from patients with clinically isolated syndromes, i.e., a first clinical manifestation of MS [23]. Histopathology studies have provided evidence of prominent demyelinating cortical lesions in MS [22, 44]. Large subpial, cortical lesions are associated with inflammatory infiltrates in the meninges and are associated with a more severe disease course [45–47]. B cells and plasma cells are present in the meningeal infiltrates and may become organized in lymphoid follicle-like structures in patients with SPMS, often associated with a more severe disease course [43, 45, 46, 48]. Accordingly, therapeutic depletion of B cells within the CNS may also be advantageous in MS.

3 Mechanisms of Anti-CD20 Antibodies

The anti-CD20 antibodies target the CD20 molecule, which is expressed on cells of the B cells lineage from the pre-B cell to the early plasmablast stage [6]. In addition, CD20 is expressed at lower levels on a subset of T cells [49]. CD20 is a member of the membrane-spanning 4-A family and is encoded by the *MS4A1* gene on chromosome 11 [50]. CD20 is a nonglycosylated molecule with a molecular weight of 33–36 kD as the intracellular region of the molecule is differentially phosphorylated on serine and threonine residues [50]. On the cell surface, CD20 is present in tetramers associated with lipid rafts and is believed to be involved in the release of calcium from intracellular stores during B-cell activation.

IgG antibodies are composed of two immunoglobulin heavy chain and two immunoglobulin light chain molecules. Parts of the light chain and heavy chain molecules constitute the paratope, which is the antigen-binding part of the immunoglobulin, whereas the heavy chains constitute the fragment crystallizable (Fc) part, which defines the effector functions of the antibody (Fig. 1). Anti-CD20 antibodies are divided into type 1 and type 2 antibodies according to the mechanisms they employ for B-cell depletion. Type 1 anti-CD20 antibodies cross-link CD20, which leads to the accumulation of aggregates of CD20 molecules in lipid rafts and allows for efficient activation of complement-dependent cytotoxicity [51]. Type 2 anti-CD20 antibodies do not cross-link CD20 molecules in rafts and do not activate complement. Instead they induce programmed cell death more efficiently than do type 1 antibodies [50]. All anti-CD20 antibodies induce antibody-dependent cellular cytotoxicity mediated by binding to the Fc domain of the antibody [52].

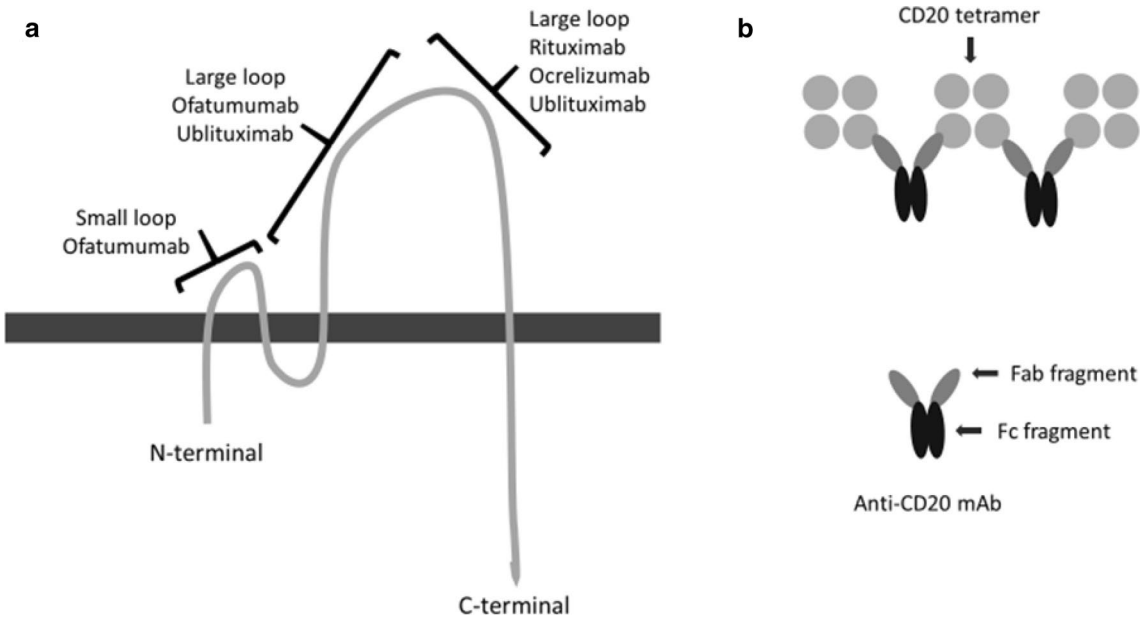

Fig. 1 **a** Monoclonal anti-CD20 antibodies rituximab, ocrelizumab, ofatumumab, and ublituximab bind to the minor and major extracellular loop of the CD20 molecule. **b** Binding of the Fab of an anti-CD20 antibody to CD20 tetramers. This results in aggregation of CD20 tetramers in lipid rafts, which allows activation of the complement cascade. Complement activation and antibody-dependent cellular cytotoxicity is mediated by the Fc fragment of the anti-CD20 antibody. *CD* cluster of differentiation, *Fab* fragment antigen binding, *Fc* fragment crystallizable, *mAb* monoclonal antibody

Rituximab is a chimeric IgG1 anti-CD20 antibody and a prototype type 1 antibody [50]. Ocrelizumab, ofatumumab, and ublituximab are also type 1 antibodies: ocrelizumab is a humanized IgG1 antibody, ofatumumab a fully human IgG1 antibody, and ublituximab a chimeric IgG1 antibody with a low fucose content in the Fc region. Ocrelizumab and rituximab bind to an overlapping epitope in the large loop of the CD20 molecule, ofatumumab binds to a more N-terminal part of the large loop as well as to the small loop, and ublituximab binds to nonoverlapping epitopes in the major loop (Fig. 1) [53, 54]. The low fucose content of the Fc region of ublituximab results in improved antibody-dependent cellular cytotoxicity activity; conversely, ofatumumab activates the complement cascade more efficiently than the other type 1 antibodies (Fig. 1) [53, 55]. Ocrelizumab has less complement-dependent cytotoxicity and more antibody-dependent cellular cytotoxicity activity than rituximab [53].

Initial in vivo studies in four patients with PPMS treated with rituximab showed efficient depletion of B cells in the blood but not in the CSF, whereas another study showed reduced T- and B-cell counts in CSF 6 months after the initiation of rituximab therapy [56, 57]. Other studies confirmed decreased B- and T-cell levels in CSF after treatment with rituximab, along with lower concentrations of several chemokines and cytokines but no major effect on intrathecal IgG synthesis [38, 58, 59]. Another study showed no elimination of clonally expanded B cells in the CSF after treatment with rituximab [60]. The incomplete elimination of B cells in CSF after systemic rituximab administration has led to attempts at treatment with intrathecal administration of rituximab, but efficacy has been lower than expected, most likely due to the presence of insufficient complement and effector cells for antibody-dependent cellular cytotoxicity to allow for efficient B-cell depletion. Insufficient depletion of circulating B cells with potential for CNS migration after intrathecal treatment may also contribute [61–63]. Conversely, a recent study of patients treated with ublituximab showed an increase in naïve T cells, a decrease in memory T cells, and an increase in regulatory T cells in blood after B-cell depletion. This is consistent with the notion that B-cell depletion may work by reducing the activation of pathogenic T cells [64]. Direct depletion of CD20-positive T cells may also contribute, but this effect is difficult to assess as the anti-CD20 antibodies used for detection of CD20-positive T cells ex vivo cross-react with several of the anti-CD20 antibodies used for B-cell depletion therapy in MS [53, 65].

Treatment with B-cell-depleting therapies can be associated with the occurrence of therapy-induced antidrug antibodies because—despite almost complete elimination of circulating B cells—B-cell depletion is less complete in lymphoid tissue. Rituximab is a chimeric antibody, and human antichimeric antibodies against rituximab often develop with treatment and are suspected to have a detrimental role in efficacy and tolerability [66]. The humanized anti-CD20 monoclonal antibody ocrelizumab and the only fully human anti-CD20 antibody ofatumumab are assumed to be less immunogenetic but may lead to development of human antihuman antibodies (HAHA) instead [7, 8].

4 Clinical Effects of Anti-CD20 Monoclonal Antibody Therapy

The clinical efficacy of and adverse events (AEs) experienced with anti-CD20 antibodies have been studied in several large phase II and phase III trials (Table 1). Table 2 provides an overview of the pivotal trials of rituximab, ocrelizumab, and ofatumumab.

Table 1 Overview of the monoclonal anti-CD20 antibodies in current use or being developed for the treatment of multiple sclerosis

Antibody	Monoclonal antibody type	Effector mechanism		Clinical trials
		CDC	ADCC	
Ocrelizumab	Humanized IgG	+	+++	RRMS phase II [10]
				RRMS OPERA I+II phase III [8]
				PPMS ORATORIO phase III [13]
Ofatumumab	Human IgG	+++	++	RRMS phase II [11]
				RRMS MIRROR phase II [7]
				RRMS ASCLEPIOS I+II phase III [76]
Rituximab	Chimeric IgG1	++	++	RRMS HERMES phase II [9]
				PPMS OLYMPUS phase III [12]
Ublituximab	Chimeric IgG1 (low fucose)	+	++++	RRMS phase II [77–79]
				RRMS phase II (ongoing) [80]

ADCC antibody-dependent cytotoxicity, *CDC* complement-dependent cytotoxicity, *Ig* immunoglobulin, *PPMS* primary progressive multiple sclerosis, *RRMS* relapsing-remitting multiple sclerosis

Table 2 Effects on relapses, 3- or 6-month worsening of symptoms in the EDSS, magnetic resonance imaging activity, and atrophy of monoclonal antibodies tested in pivotal trials (relative reduction vs. comparator)

Monoclonal antibody and comparator	Relapses (%)	Worsening in EDSS (%)	Improvement in EDSS (%)	MRI new or newly enlarged T2 lesions	Atrophy (%)
Rituximab vs. placebo [9][a]	50*	NA	NA	96***	NA
Ocrelizumab vs. IFN-β-1a [8][b]	46***/47***	43**/37*	61**/14 (NS)	77***/83***	23**/15 (NS)
Ofatumumab vs. teriflunomide [76][c/d]	51***/58*** [c]	34** [d]	35 (NS) [d]	82***/85*** [c]	NS/NS [c]

EDSS Expanded Disability Status Scale, *IFN* interferon, *MRI* magnetic resonance imaging, *NA* not applicable, *NS* not statistically significant

*$p < 0.05$, **$p < 0.01$, ***$p < 0.001$

[a]HERMES (phase II)

[b]OPERA I/OPERA II (phase III)

[c]ASCLEPIOS I/ASCLEPIOS II (phase III)

[d]ASCLEPIOS I + ASCLEPIOS II (phase III)

4.1 Rituximab: Clinical Results and Adverse Effects

The chimeric monoclonal antibody rituximab was the first anti-CD20 monoclonal antibody to be used for treatment of MS. In an open-label, multicenter trial evaluating preliminary safety and tolerability, rituximab was administered as two infusions of 1 g each on days 1 and 15 in 26 patients with RRMS. Adverse effects were mostly mild or moderate fatigue, headache, or muscle weakness. More than half of the patients (65.4%) reported infusion-related reactions following the first cycle, which decreased significantly to 8% after the second cycle, and no serious AEs or infections were reported. The annualized relapse rate was reduced to 0.18 on week 72 compared with 1.27 in the year before the study, and most subjects (80.8%) remained relapse free [67].

A phase II, double-blind, placebo-controlled efficacy and safety trial of 104 patients with RRMS, randomized to receive a single course of intravenous rituximab 1 g or placebo on days 1 and 15, was published shortly after [9]. The primary endpoint was the total number of gadolinium-enhancing lesions from week 12 to 24, which was significantly reduced by 91% ($p < 0.001$); furthermore, a significant reduction of annualized relapse rate of 58% at week 24 ($p = 0.04$) and 50% at week 48 ($p = 0.08$) was demonstrated when comparing rituximab with placebo. Another phase II/III, randomized, double-blind, parallel-group, placebo-controlled, multicenter study of 439 patients with PPMS, randomized 2:1 to receive repeated courses of two intravenous infusions of rituximab 1 g each, 2 weeks apart or placebo infusions every 24 weeks through 96 weeks, did not reach the primary endpoint, since there was no significant reduction in time to confirmed disease progression after 96 weeks [12]. Although one secondary MRI endpoint, reduction in T2 lesion volume, was reached, the other, brain volume change, was not different from placebo. A subgroup analysis showed a delay in time to confirmed disease progression in patients aged < 51 years and a reduction of gadolinium-enhancing lesions in the same subgroup, which led the authors to conclude that B-cell depletion with rituximab might be efficacious in younger patients with PPMS with inflammatory disease activity [9].

The safety evaluation of these two randomized controlled trials was generally favorable: although more infusion-related reactions were recorded within the first 24 h compared with placebo (78% and 40%, respectively), the number of infusion-related reactions was reduced in the rituximab group after the second infusion (20 vs. 40%). Serious infections were more pronounced in rituximab-treated patients (4.5% with rituximab and < 1.0% with placebo), but AEs were mostly mild to moderate [9, 12].

Human antidrug antibodies were detected in 24.6% of patients treated with rituximab after a mean of 11.1 months after randomization, but no association between antidrug antibodies and AEs or efficacy measures was noted [9]. Antidrug antibodies were reported in a higher proportion of Swedish patients after off-label rituximab therapy [66]. In the Swedish patients, antidrug antibodies were observed in 37% of patients with RRMS and 26% of patients with PPMS. The presence of antidrug antibodies decreased after repeated rituximab infusions. Antidrug antibodies were associated with incomplete B-cell depletion, but only four patients with antidrug antibodies in the entire cohort of 339 patients discontinued therapy, and there was no association between the presence or titer of antibodies and infusion reactions or other AEs.

A small MRI-blinded phase II trial evaluated the safety, efficacy, and tolerability of add-on intravenous rituximab administered four times at a dose of 375 mg/m^2 weekly in 30 patients with breakthrough disease while receiving standard injectable therapy (interferon-β-1a/b or glatiramer acetate). The primary endpoint was MRI disease activity, and the study demonstrated that 74% of the post-treatment MRI scans were free of gadolinium-enhancing lesions compared

with 26% at baseline ($p < 0.0001$). Standard injectable therapy with add-on rituximab was generally well-tolerated, and few AEs were reported [68].

Smaller studies and clinical observations have also confirmed disease activity reduction with rituximab, although further exploration of efficacy in RRMS has not been carried out in phase III trials [69–71].

A large cohort of Swedish patients with MS ($N = 822$: RRMS $n = 557$, SPMS $n = 198$, PPMS $n = 67$) participated in a retrospective uncontrolled observational multicenter study using off-label rituximab therapy [72]. The study showed very low annualized relapse rates during treatment (0.044, 0.038, and 0.015, respectively). Furthermore, at baseline, 26.2% had contrast-enhancing lesions compared with 4.6% of those receiving rituximab therapy. The median Expanded Disability Status Scale (EDSS) score remained unchanged in RRMS ($p = 0.42$) and increased by 0.5 and 1.0 in SPMS and PPMS, respectively ($p = 0.10$ and 0.25). Infusion-related AEs occurred during 7.8% of infusions; most were mild. A total of 89 AEs of grade 2 or higher (of which 76 were infections) were recorded in 72 patients. There were no major safety concerns and no cases of progressive multifocal leukoencephalopathy (PML) [72]. Another Swedish study also reported the high efficacy of rituximab as a first-line therapy in newly diagnosed MS [73]. In this study, the lowest discontinuation rate was reported for rituximab when compared with all other disease-modifying therapies, including fingolimod and natalizumab, and disease activity (relapses and/or MRI activity) was significantly lower for rituximab than for injectable disease-modifying therapies and dimethyl fumarate [73].

4.2 Ocrelizumab: Clinical Results and Adverse Effects

The efficacy and safety of ocrelizumab, a humanized anti-CD20 monoclonal antibody, was explored in a phase II, randomized, placebo-controlled multicenter trial in patients with relapsing-remitting disease course, assigned to either (1) placebo administered at day 1 and day 15 in the first cycle and low-dose intravenous ocrelizumab 300 mg administered at day 1 and day 15 in the second cycle ($N = 54$); (2) low-dose cycles of intravenous ocrelizumab 300 mg administered at day 1 and day 15 in the first cycle and 600 mg administered at day 1 in the second cycle ($N = 56$); (3) high-dose cycles of intravenous ocrelizumab 1000 mg administered at day 1 and day 15 in the first cycle and 1000 mg administered at day 1 in the second cycle ($N = 55$), or (4) intramuscular injections of interferon-β-1a 30 µg once weekly ($N = 55$) [10]. The primary outcome of the study was the total number of gadolinium-enhancing lesions on MRI, which was significantly lower in both ocrelizumab groups than in the placebo group (5.5 for placebo; 0.6 for ocrelizumab 600 mg, an 89% relative reduction; and 0.2 for ocrelizumab 2000 mg, a 96% relative reduction; both $p < 0.001$). The total number of gadolinium-enhancing lesions was 6.9 for interferon-β-1a, and exploratory analyses showed that results in both ocrelizumab groups were superior to those for interferon-β-1a. In addition, the annualized relapse rate was significantly reduced in both ocrelizumab groups (0.13 with ocrelizumab 600 mg; 0.17 with ocrelizumab 2000 mg) compared with 0.64 in the placebo group [10]. An open-label extension phase of the study showed minimal MRI activity at week 144 and continued low annualized relapse rate in both ocrelizumab groups [74].

No major safety concerns were reported in the double-blind phase II study or in the extension study. Serious AEs and infections were comparable in all treatment groups, but one patient died in the high-dose ocrelizumab group of the double-blind phase II study due to acute-onset thrombotic microangiopathy, and a possible relation to ocrelizumab could not be excluded. Infusion-related AEs were increased in the two ocrelizumab groups (35% in the low-dose ocrelizumab, 44% in the high-dose ocrelizumab, and 9% in the placebo group). In the extension study, infection rates were 6.5% for low-dose ocrelizumab and 11.1% for high-dose ocrelizumab, mostly due to respiratory and urinary tract infections. Ocrelizumab was well-tolerated, with mild or moderate infusion-related reactions during the first infusion being the most common adverse effect [10, 74].

The treatment efficacy and safety of ocrelizumab in patients with RRMS was furthermore demonstrated in two identical, double-blind, randomized phase III trials in patients with RRMS: The OPERA I and II trials [8] included 821 and 835 patients randomized (1:1) to intravenous ocrelizumab 600 mg every 24 weeks or subcutaneous interferon-β-1a 44 µg three times weekly over a treatment period of 96 weeks. The primary endpoint was annualized relapse rate, which was reduced by 46% and 47%, respectively, compared with interferon-β-1a ($p < 0.0001$). The secondary clinical endpoint, 3-month confirmed EDSS disability worsening, was reduced by 43% and 37%, respectively ($p < 0.05$), and 3-month confirmed improvement in EDSS disability was increased by 61% ($p = 0.01$) and 15% (not significant), respectively. The number of gadolinium-enhancing lesions was reduced by 94% and 95%, and new or enlarged T2 MRI lesions were reduced by 77% and 83% compared with interferon-β-1a [8]. When 'no evidence of disease activity' criteria (i.e., no relapses, disability worsening, or new/enlarged or enhancing lesions on MRI) were applied, 47.9% and 47.5% of patients receiving ocrelizumab met the criteria at 96 weeks, which was a relative increase of 64% and 89% compared with interferon-β-1a ($p < 0.0001$) [75].

AEs in the OPERA I and II studies were reported by 80.1% and 86.3% in the ocrelizumab groups compared with

80.9% and 85.6% in the interferon-β-1a groups, respectively. The most common AEs were infusion reactions, nasopharyngitis, upper respiratory tract infection, headache, and urinary tract infection in patients treated with ocrelizumab. Serious AEs were reported in 6.9% and 7.0% of patients treated with ocrelizumab and in 7.8% and 9.6% of patients treated with interferon-β-1a, and the OPERA studies reported no major safety concerns. In the OPERA trials, antidrug-binding antibodies developed in 3 of 825 patients (0.4%) who received ocrelizumab, whereas neutralizing antibodies occurred in one patient [8].

The phase III ORATORIO study included 732 patients with PPMS. This was a double-blind, randomized and placebo-controlled study that randomized patients (2:1) to intravenous ocrelizumab 600 mg or placebo every 24 weeks for at least 120 weeks [13]. The primary endpoint, 3-month confirmed disability worsening, showed a significant reduction of 24% in ocrelizumab-treated patients compared with placebo-treated patients and a significant 25% reduction in 6-month confirmed disability worsening. Worsening of walking speed with confirmation after 24 weeks was reduced by 29%. The increase in MRI T2 lesion area was 7.4% in the placebo group and − 3.4% in the ocrelizumab group. Safety evaluation revealed that 95.1% of patients had at least one AE after treatment with ocrelizumab and 90.0% of patients had at least one AE after placebo. Serious AEs were reported in 20.4% of patients receiving ocrelizumab and 22.2% of patients receiving placebo. Overall, the rates of AEs did not differ significantly between the ocrelizumab and placebo groups [13].

In the three phase III ocrelizumab studies, infusion reactions most commonly occurred with the first infusion, in line with previous observations. Use of premedication, particularly antihistamines, was associated with fewer infusion reactions. Severe infusion reactions were reported in 2.4% of ocrelizumab-treated patients in the OPERA studies (vs. 0.1% with interferon-β-1a) and 1.2% of ocrelizumab-treated patients in ORATORIO (vs. 1.7% with placebo) [8, 13]. One life-threatening adverse reaction (bronchospasm) occurred in an ocrelizumab-treated patient 15 min after infusion initiation [8].

In the ORATORIO study, significantly more malignancies were reported with ocrelizumab than with placebo (2.3 vs. 0.8%). This included four breast cancers, one endometrial adenocarcinoma, one anaplastic lymphoma, one histiocytoma, one metastatic pancreatic cancer, and three basal cell carcinomas. The absolute number was comparable to that in the general population, but future studies need to target stratification regarding specific forms of cancer [76].

No cases of PML were reported in the ocrelizumab MS trials, but eight cases of PML (as of September 2019) have been described in postmarketing surveillance, seven of which occurred after switching from natalizumab or fingolimod to ocrelizumab, most likely due to a "carry-over" effect, whereas the most recent case was designated a non-carry-over case [85].

In 2017, the US FDA approved ocrelizumab as the first treatment indicated for both RRMS and PPMS; it was approved by the European Medicines Agency in 2018.

4.3 Ofatumumab: Clinical Results and Adverse Effects

The first published study of the fully human antibody ofatumumab in MS was a phase II randomized, double-blind, placebo-controlled study of 38 patients with RRMS who received two intravenous infusions of ofatumumab 100 mg, 300 mg, or 700 mg or placebo 2 weeks apart [11]. All doses induced a substantial reduction in new brain MRI lesion activity (> 99%) in the first 24 weeks after ofatumumab administration as well as significant reductions of new T1 gadolinium-enhancing lesions, total enhancing T1 lesions, and new/enlarging T2 lesions.

Intravenous ofatumumab was well-tolerated, and no unexpected safety signals or dose-related safety concerns were observed. The most common AEs were infusion reactions, infections, rash, erythema, throat irritation, fatigue, and flushing. Infusion-related reactions were most often mild and were common on the first day of ofatumumab dosing, even with premedication, but were not observed on the second infusion day. The occurrence of infections was similar in the ofatumumab and placebo treatment groups. None of the patients in this study tested positive for antidrug antibodies [11].

A larger dose-finding phase II double-blind, placebo-controlled, parallel-group study (MIRROR) of subcutaneous ofatumumab comprised 232 patients with RRMS [7]. The patients were randomized to one of five treatment groups: placebo, ofatumumab 3 mg every 12 weeks, ofatumumab 30 mg every 12 weeks, ofatumumab 60 mg every 12 weeks, or ofatumumab 60 mg every 4 weeks. All patients continued in the study for 24 weeks of treatment and were followed-up until B-cell repletion. The mean cumulative number of new T1 gadolinium-enhancing lesions for each ofatumumab dose regimen from baseline to week 12 was reduced by 65% ($p < 0.001$), and the corresponding data analysis of weeks 4–12 estimated ≥ 90% reductions for each dose ≥ 30 mg ($p < 0.0019$). Interestingly, ofatumumab dosage regimens that did not completely deplete circulating B cells could still achieve robust treatment effects. A dose-dependent CD19 B-cell depletion was seen across regimens. The rate of B-cell repletion following cessation of dosing was similar, with a delay of approximately 4 weeks in the group receiving 60 mg every 4 weeks. Overall, 26 patients relapsed during the first 12 weeks, 11 (42%) of whom relapsed during the first 4 weeks. Over the 24-week period, 17 (25%) patients

relapsed in the placebo group versus three to ten patients (9–22%) across the ofatumumab groups. Most patients (79%) had unchanged EDSS scores at weeks 12 and 24.

AEs were largely mild to moderate in severity. The incidence was highest in the ofatumumab 60 mg every 4 weeks group during weeks 0–12 of treatment. The most frequent AE was injection-related reactions in week 0–12, occurring at a rate of 41–66% in the ofatumumab groups versus 15% in the placebo group. Most were associated with the first dose of ofatumumab and resolved within 1 day of onset. In total, eight patients discontinued because of AEs, of whom two patients discontinued because of injection-related reactions and two patients because of decreased IgG [7]. Four patients had a single positive low-titer result for HAHA during the treatment phase, and one patient also had a positive titer during follow-up but was negative at week 48. The B-cell depletion did not seem to be affected [7].

Recently, the results of two identical phase III studies (ASCLEPIOS I and II trials) were presented at ECTRIMS 2019 [77]. Subcutaneous ofatumumab 20 mg every 4 weeks was compared with oral teriflunomide 14 mg daily in two identical double-blind, double-dummy, parallel-group trials. In the ASCLEPIOS I and II trials, patients were randomized to either ofatumumab (465 and 481 patients) or teriflunomide (462 and 474 patients). Approximately two-thirds were women, the mean age was 38 years, and disease duration was 8 years. At baseline, the mean EDSS was 2.9, the mean relapse rate in the previous 12 months was 1.3, approximately 40% had gadolinium-enhancing lesions, and 60% had been previously treated with disease-modifying therapies. The primary endpoint, the annualized relapse rate, was 0.11 and 0.10 in the ofatumumab groups and 0.22 and 0.25 in the teriflunomide groups in ASCLEPIOS I and II, respectively, yielding a relative reduction of 50.5% and 58.5%, respectively (both $p<0.001$). Pooled analysis of ASCLEPIOS I and II data showed that ofatumumab reduced 3-month confirmed disability worsening by 34.4% ($p=0.002$) and 6-month confirmed disability worsening by 32.5% ($p=0.012$) and disclosed a trend toward better 6-month confirmed improvement in EDSS (hazard ratio 1.35; 95% confidence interval 0.95–1.92; $p=0.094$). In ASCLEPIOS I, the reduction in gadolinium-enhancing lesions was 97.5% and the reduction in new/enlarging T2 lesions was 82%; in ASCLEPIOS II, the corresponding reductions were 93.8% and 84.5% compared with teriflunomide therapy. There were no differences in the slope of brain volume reduction between ofatumumab and teriflunomide, whereas ofatumumab significantly reduced neurofilament light concentrations in serum compared with teriflunomide [77].

Ofatumumab seemed to have a favorable safety profile with no unexpected safety signals. Infusion-related reactions were more frequent with ofatumumab, but—notably—only the first injection was associated with more frequent reactions compared with placebo. Serious AEs included infections in 1.8% and 2.5% and malignancies in 0.3% and 0.5% for teriflunomide and ofatumumab, respectively. No opportunistic infections were reported. More than 80% of the patients completed the studies [77].

The subcutaneous administration of ofatumumab may have the advantages of more convenient self-administration of the treatment at home but may not be well-controlled in noncompliant patients and must be monitored by the treating physician as with intravenous administration.

Ofatumumab is expected to be approved for treatment of relapsing forms of MS in 2020.

4.4 Ublituximab: Clinical Results and Adverse Effects

Ublituximab is a third-generation glycoengineered chimeric anti-CD20 antibody. There are only limited studies on the clinical effects of ublituximab in MS. In a phase II study of 48 patients with active disease, i.e., two or more relapses in the previous 2 years or one relapse and/or one gadolinium-enhancing lesion in the past year, 32 women and 16 men with a mean age of 39.2 years and a mean disease duration of 7.4 years were enrolled [78]. The patients were randomly assigned to treatment with different doses of ublituximab intravenously. All patients initially received ublituximab 150 mg (week 1) and either ublituximab 450 or 600 mg at week 3 (14 days after the initial dose) and at week 24 and were then followed for 48 weeks. The median B-cell depletion was > 99% at the primary analysis point at week 4 and was maintained at this low level at week 24 and 48. T cells showed a significant population shift toward naïve and regulatory cells. At baseline, the mean number of T1 gadolinium-enhancing lesions was 3.8; this was reduced to zero (100% reduction) at week 24 ($p=0.003$) and maintained at zero at week 48 ($p=0.0004$). T2 lesion volume had decreased by 8% at week 24 ($p=0.004$) and 10% at week 48 ($p=0.016$). Overall, the annualized relapse rate was 0.07, 93% of the patients were relapse free at week 48, and no patients demonstrated sustained disability worsening. The most common AE was infusion reactions that were all grade 1 or 2; no severe AEs were reported. No serious or opportunistic infections and no liver diseases occurred [78–80]. Ublituximab is currently being tested against teriflunomide in two fully enrolled phase III studies (ULTIMATE I AND II) in patients with RRMS (ClinicalTrials.gov identifier: NCT03277261 and NCT03277248) [81].

5 Conclusions

After systemic administration, anti-CD20 monoclonal antibodies induce profound B-cell depletion via mechanisms that are not fully elucidated but include

complement-dependent and antibody-dependent cell-mediated cytotoxicity. However, the role of these mechanisms does differ between the four individual anti-CD20 antibodies currently used or in development for the treatment of MS, and the effect of these antibodies on CD20-positive T cells, which may also be a target of anti-CD20 antibody therapy, is poorly understood. Although systemic treatment with ocrelizumab showed some efficacy in delaying disability in PPMS, efficacy was limited compared with that observed in RRMS. In contrast, intrathecal administration has shown disappointing results, presumably because of the lack of effector mechanisms in the intrathecal compartment. Future studies should address whether the intrathecal administration of anti-CD20 antibodies that directly induce B-cell depletion is more efficacious, especially in patients with PPMS, where intrathecal B-cell responses can be very prominent.

In RRMS, B-cell depletion is associated with a reduction in disease activity and in disability worsening, and the effect on MRI activity is remarkably pronounced. Any differences in the effect on MS disease activity between the anti-CD20 monoclonal antibodies is difficult to assess because the anti-CD20 antibodies have been compared with different disease-modifying treatments or placebo, but overall no conspicuous difference in efficacy seems to be present. The short-term safety profile in the phase III studies appears favorable, but changes in the immunoglobulin profile may be associated with an increased risk of infections, and the risk of malignancies should be followed carefully. However, anti-CD20 monoclonal antibodies are important therapies for relapsing forms of MS and have also shown effect in early PPMS where focal inflammation is still prominent.

Studies in Cynomolgus monkeys have confirmed the notion that, despite almost complete elimination of circulating B cells, B-cell depletion is less complete in lymphoid tissue [82]. This explains why some preservation of B-cell responses, including the development of antidrug antibodies, has been observed in some patients in spite of anti-CD20 antibody therapy. Future studies should address the extent of B-cell depletion needed to maintain a disease activity-free status, as less complete depletion of circulating B cells may be sufficient, at least in some patients, and may be associated with a lower risk of long-term suppression of antibody responses.

The effect of long-term anti-CD20 therapy for neuroinflammatory diseases is not fully clarified, but—overall—long-term depletion of peripheral B cells appears safe and efficacious [83]. However, patients may develop hypogammaglobulinemia following treatment, with some demonstrating failure of B-cell recovery. The clinical significance remains controversial, but severe recurrent infections have been reported in patients treated with rituximab for neuromyelitis optica spectrum disorder, although most patients are relatively asymptomatic [84]. In the ORATORIO study in PPMS, treatment with ocrelizumab resulted in a higher proportion of patients with IgM levels below the lower limit of normal with no apparent relationship with serious infections [13]. Significantly more malignancies were reported with ocrelizumab than with placebo, but the overall incidence rate for cancer was not different from the expected, and long-term follow-up of large cohorts of patients will be needed to assess any increased risk of malignancies.

Using a dosage of intravenous ocrelizumab 600 mg every 24 weeks, B-cell counts were nearly completely depleted just before administration of the next ocrelizumab dose [8]; however, interestingly, administration of lower doses of subcutaneous ofatumumab every 12 weeks with incomplete B-cell depletion had a high capacity to suppress new brain MRI lesions [7]. Hence, less than complete B-cell depletion may be clinically efficacious with fewer long-term adverse effects.

Compliance with Ethical Standards

Funding No sources of funding were used to prepare this manuscript.

Conflict of interest F Sellebjerg has served on scientific advisory boards, been on steering committees of clinical trials, served as a consultant, received support for congress participation, received speaker honoraria, or received research support for his laboratory from Biogen, Merck, Novartis, Roche, Sanofi Genzyme, and Teva. M. Blinkenberg has received personal compensation for serving on scientific advisory boards for Genzyme, Roche, Biogen, Merck, Novartis, and Teva; has received speaker honoraria from Genzyme, Biogen, Merck, Novartis, Teva, and Roche; has received consulting honoraria from the Danish Multiple Sclerosis Society, Biogen, Teva, Roche, and Merck; and has received funding for travel from Genzyme, Roche, and Biogen. P. S. Sorensen has received personal compensation for serving on scientific advisory boards, steering committees, or independent data monitoring boards for Biogen, Merck, Novartis, Teva, GlaxoSmithKline, MedDay Pharmaceuticals, Genzyme, Celgene, and Forward Pharma, and has received speaker honoraria from Biogen, Merck, Teva, Genzyme, and Novartis.

References

1. Baecher-Allan C, Kaskow BJ, Weiner HL. Multiple sclerosis: mechanisms and immunotherapy. Neuron. 2018;97(4):742–68.
2. Lublin FD, Reingold SC, Cohen JA, Cutter GR, Sorensen PS, Thompson AJ, et al. Defining the clinical course of multiple sclerosis: the 2013 revisions. Neurology. 2014;83(3):278–86.
3. Sormani MP, Bruzzi P. MRI lesions as a surrogate for relapses in multiple sclerosis: a meta-analysis of randomised trials. Lancet Neurol. 2013;12(7):669–76.
4. Sorensen PS, Sellebjerg F. Pulsed immune reconstitution therapy in multiple sclerosis. Ther Adv Neurol Disord. 2019;12:1756286419836913.
5. Sellebjerg F, Sorensen PS. Therapeutic interference with leukocyte recirculation in multiple sclerosis. Eur J Neurol. 2015;22(3):434–42.

6. Li R, Patterson KR, Bar-Or A. Reassessing B cell contributions in multiple sclerosis. Nat Immunol. 2018;19(7):696–707.
7. Bar-Or A, Grove RA, Austin DJ, Tolson JM, VanMeter SA, Lewis EW, et al. Subcutaneous ofatumumab in patients with relapsing-remitting multiple sclerosis: the MIRROR study. Neurology. 2018;90(20):e1805–14.
8. Hauser SL, Bar-Or A, Comi G, Giovannoni G, Hartung HP, Hemmer B, et al. Ocrelizumab versus interferon beta-1a in relapsing multiple sclerosis. N Engl J Med. 2017;376(3):221–34.
9. Hauser SL, Waubant E, Arnold DL, Vollmer T, Antel J, Fox RJ, et al. B-cell depletion with rituximab in relapsing-remitting multiple sclerosis. N Engl J Med. 2008;358(7):676–88.
10. Kappos L, Li D, Calabresi PA, O'Connor P, Bar-Or A, Barkhof F, et al. Ocrelizumab in relapsing-remitting multiple sclerosis: a phase 2, randomised, placebo-controlled, multicentre trial. Lancet. 2011;378(9805):1779–87.
11. Sorensen PS, Lisby S, Grove R, Derosier F, Shackelford S, Havrdova E, et al. Safety and efficacy of ofatumumab in relapsing-remitting multiple sclerosis: a phase II study. Neurology. 2014;2014(82):573–81.
12. Hawker K, O'Connor P, Freedman MS, Calabresi PA, Antel J, Simon J, et al. Rituximab in patients with primary progressive multiple sclerosis: results of a randomized double-blind placebo-controlled multicenter trial. Ann Neurol. 2009;66(4):460–71.
13. Montalban X, Hauser SL, Kappos L, Arnold DL, Bar-Or A, Comi G, et al. Ocrelizumab versus placebo in primary progressive multiple sclerosis. N Engl J Med. 2017;376(3):209–20.
14. Consortium IMSG. Multiple sclerosis genomic map implicates peripheral immune cells and microglia in susceptibility. Science. 2019;365(6460).
15. Thompson AJ, Banwell BL, Barkhof F, Carroll WM, Coetzee T, Comi G, et al. Diagnosis of multiple sclerosis: 2017 revisions of the McDonald criteria. Lancet Neurol. 2018;17(2):162–73.
16. Stangel M, Fredrikson S, Meinl E, Petzold A, Stuve O, Tumani H. The utility of cerebrospinal fluid analysis in patients with multiple sclerosis. Nat Rev Neurol. 2013;9(5):267–76.
17. Bankoti J, Apeltsin L, Hauser SL, Allen S, Albertolle ME, Witkowska HE, et al. In multiple sclerosis, oligoclonal bands connect to peripheral B-cell responses. Ann Neurol. 2014;75(2):266–76.
18. Walsh MJ, Tourtellotte WW. Temporal invariance and clonal uniformity of brain and cerebrospinal IgG, IgA, and IgM in multiple sclerosis. J Exp Med. 1986;163(1):41–53.
19. Ritchie AM, Gilden DH, Williamson RA, Burgoon MP, Yu X, Helm K, et al. Comparative analysis of the $CD19^+$ and $CD138^+$ cell antibody repertoires in the cerebrospinal fluid of patients with multiple sclerosis. J Immunol. 2004;173(1):649–56.
20. von Budingen HC, Kuo TC, Sirota M, van Belle CJ, Apeltsin L, Glanville J, et al. B cell exchange across the blood-brain barrier in multiple sclerosis. J Clin Investig. 2012;122(12):4533–43.
21. Stern JN, Yaari G, Vander Heiden JA, Church G, Donahue WF, Hintzen RQ, et al. B cells populating the multiple sclerosis brain mature in the draining cervical lymph nodes. Sci Transl Med. 2014;6(248):248ra107.
22. Lassmann H. Pathogenic mechanisms associated with different clinical courses of multiple sclerosis. Front Immunol. 2018;9:3116.
23. Sellebjerg F, Jaliashvili I, Christiansen M, Garred P. Intrathecal activation of the complement system and disability in multiple sclerosis. J Neurol Sci. 1998;157(2):168–74.
24. Scolding NJ, Morgan BP, Houston WA, Linington C, Campbell AK, Compston DA. Vesicular removal by oligodendrocytes of membrane attack complexes formed by activated complement. Nature. 1989;339(6226):620–2.
25. Keegan M, Konig F, McClelland R, Bruck W, Morales Y, Bitsch A, et al. Relation between humoral pathological changes in multiple sclerosis and response to therapeutic plasma exchange. Lancet. 2005;366(9485):579–82.
26. Lucchinetti C, Bruck W, Parisi J, Scheithauer B, Rodriguez M, Lassmann H. Heterogeneity of multiple sclerosis lesions: implications for the pathogenesis of demyelination. Ann Neurol. 2000;47(6):707–17.
27. Elliott C, Lindner M, Arthur A, Brennan K, Jarius S, Hussey J, et al. Functional identification of pathogenic autoantibody responses in patients with multiple sclerosis. Brain. 2012;135(Pt 6):1819–33.
28. Molnarfi N, Schulze-Topphoff U, Weber MS, Patarroyo JC, Prod'homme T, Varrin-Doyer M, et al. MHC class II-dependent B cell APC function is required for induction of CNS autoimmunity independent of myelin-specific antibodies. J Exp Med. 2013;210(13):2921–37.
29. Jelcic I, Al Nimer F, Wang J, Lentsch V, Planas R, Jelcic I, et al. Memory B cells activate brain-homing, autoreactive CD4(+) T cells in multiple sclerosis. Cell. 2018;175(1):85–100e23.
30. Barr TA, Shen P, Brown S, Lampropoulou V, Roch T, Lawrie S, et al. B cell depletion therapy ameliorates autoimmune disease through ablation of IL-6-producing B cells. J Exp Med. 2012;209(5):1001–10.
31. Chen D, Ireland SJ, Remington G, Alvarez E, Racke MK, Greenberg B, et al. CD40-mediated NF-kappaB activation in B cells is increased in multiple sclerosis and modulated by therapeutics. J Immunol. 2016;197(11):4257–65.
32. Bar-Or A, Fawaz L, Fan B, Darlington PJ, Rieger A, Ghorayeb C, et al. Abnormal B-cell cytokine responses a trigger of T-cell-mediated disease in MS? Ann Neurol. 2010;67(4):452–61.
33. Schneider R, Mohebiany AN, Ifergan I, Beauseigle D, Duquette P, Prat A, et al. B cell-derived IL-15 enhances CD8 T cell cytotoxicity and is increased in multiple sclerosis patients. J Immunol. 2011;187(8):4119–28.
34. Li R, Rezk A, Miyazaki Y, Hilgenberg E, Touil H, Shen P, et al. Proinflammatory GM-CSF-producing B cells in multiple sclerosis and B cell depletion therapy. Sci Transl Med. 2015;7(310):310ra166.
35. McWilliam O, Sellebjerg F, Marquart HV, von Essen MR. B cells from patients with multiple sclerosis have a pathogenic phenotype and increased LTalpha and TGFbeta1 response. J Neuroimmunol. 2018;15(324):157–64.
36. Fillatreau S, Sweenie CH, McGeachy MJ, Gray D, Anderton SM. B cells regulate autoimmunity by provision of IL-10. Nat Immunol. 2002;3(10):944–50.
37. Shen P, Roch T, Lampropoulou V, O'Connor RA, Stervbo U, Hilgenberg E, et al. IL-35-producing B cells are critical regulators of immunity during autoimmune and infectious diseases. Nature. 2014;507(7492):366–70.
38. Piancone F, Saresella M, Marventano I, La Rosa F, Zoppis M, Agostini S, et al. B lymphocytes in multiple sclerosis: Bregs and BTLA/CD272 expressing-$CD19^+$ lymphocytes modulate disease severity. Sci Rep. 2016;14(6):29699.
39. Duddy M, Niino M, Adatia F, Hebert S, Freedman M, Atkins H, et al. Distinct effector cytokine profiles of memory and naive human B cell subsets and implication in multiple sclerosis. J Immunol. 2007;178(10):6092–9.
40. Knippenberg S, Peelen E, Smolders J, Thewissen M, Menheere P, Cohen Tervaert JW, et al. Reduction in IL-10 producing B cells (Breg) in multiple sclerosis is accompanied by a reduced naive/memory Breg ratio during a relapse but not in remission. J Neuroimmunol. 2011;239(1–2):80–6.
41. Lehmann-Horn K, Schleich E, Hertzenberg D, Hapfelmeier A, Kumpfel T, von Bubnoff N, et al. Anti-CD20 B-cell depletion enhances monocyte reactivity in neuroimmunological disorders. J Neuroinflammation. 2011;26(8):146.

42. Machado-Santos J, Saji E, Troscher AR, Paunovic M, Liblau R, Gabriely G, et al. The compartmentalized inflammatory response in the multiple sclerosis brain is composed of tissue-resident $CD8^+$ T lymphocytes and B cells. Brain. 2018;141(7):2066–82.
43. Frischer JM, Bramow S, Dal-Bianco A, Lucchinetti CF, Rauschka H, Schmidbauer M, et al. The relation between inflammation and neurodegeneration in multiple sclerosis brains. Brain. 2009;132(Pt 5):1175–89.
44. Fischer MT, Wimmer I, Hoftberger R, Gerlach S, Haider L, Zrzavy T, et al. Disease-specific molecular events in cortical multiple sclerosis lesions. Brain. 2013;136(Pt 6):1799–815.
45. Magliozzi R, Howell O, Vora A, Serafini B, Nicholas R, Puopolo M, et al. Meningeal B-cell follicles in secondary progressive multiple sclerosis associate with early onset of disease and severe cortical pathology. Brain. 2007;130(Pt 4):1089–104.
46. Magliozzi R, Howell OW, Reeves C, Roncaroli F, Nicholas R, Serafini B, et al. A gradient of neuronal loss and meningeal inflammation in multiple sclerosis. Ann Neurol. 2010;68(4):477–93.
47. Choi SR, Howell OW, Carassiti D, Magliozzi R, Gveric D, Muraro PA, et al. Meningeal inflammation plays a role in the pathology of primary progressive multiple sclerosis. Brain. 2012;135(Pt 10):2925–37.
48. Serafini B, Rosicarelli B, Magliozzi R, Stigliano E, Aloisi F. Detection of ectopic B-cell follicles with germinal centers in the meninges of patients with secondary progressive multiple sclerosis. Brain Pathol. 2004;14(2):164–74.
49. von Essen MR, Ammitzboll C, Hansen RH, Petersen ERS, McWilliam O, Marquart HV, et al. Proinflammatory $CD20^+$ T cells in the pathogenesis of multiple sclerosis. Brain. 2019;142:120–32.
50. Beers SA, Chan CH, French RR, Cragg MS, Glennie MJ. CD20 as a target for therapeutic type I and II monoclonal antibodies. Semin Hematol. 2010;47(2):107–14.
51. Cragg MS, Morgan SM, Chan HT, Morgan BP, Filatov AV, Johnson PW, et al. Complement-mediated lysis by anti-CD20 mAb correlates with segregation into lipid rafts. Blood. 2003;101(3):1045–52.
52. Boross P, Leusen JH. Mechanisms of action of CD20 antibodies. Am J Cancer Res. 2012;2(6):676–90.
53. Klein C, Lammens A, Schafer W, Georges G, Schwaiger M, Mossner E, et al. Epitope interactions of monoclonal antibodies targeting CD20 and their relationship to functional properties. MAbs. 2013;5(1):22–33.
54. Sawas A, Farber CM, Schreeder MT, Khalil MY, Mahadevan D, Deng C, et al. A phase 1/2 trial of ublituximab, a novel anti-CD20 monoclonal antibody, in patients with B-cell non-Hodgkin lymphoma or chronic lymphocytic leukaemia previously exposed to rituximab. Br J Haematol. 2017;177(2):243–53.
55. de Romeuf C, Dutertre CA, Le Garff-Tavernier M, Fournier N, Gaucher C, Glacet A, et al. Chronic lymphocytic leukaemia cells are efficiently killed by an anti-CD20 monoclonal antibody selected for improved engagement of FcgammaRIIIA/CD16. Br J Haematol. 2008;140(6):635–43.
56. Monson NL, Cravens PD, Frohman EM, Hawker K, Racke MK. Effect of rituximab on the peripheral blood and cerebrospinal fluid B cells in patients with primary progressive multiple sclerosis. Arch Neurol. 2005;62(2):258–64.
57. Cross AH, Stark JL, Lauber J, Ramsbottom MJ, Lyons JA. Rituximab reduces B cells and T cells in cerebrospinal fluid of multiple sclerosis patients. J Neuroimmunol. 2006;180(1–2):63–70.
58. de Flon P, Soderstrom L, Laurell K, Dring A, Sundstrom P, Gunnarsson M, et al. Immunological profile in cerebrospinal fluid of patients with multiple sclerosis after treatment switch to rituximab and compared with healthy controls. PLoS One. 2018;13(2):e0192516.
59. Piccio L, Naismith RT, Trinkaus K, Klein RS, Parks BJ, Lyons JA, et al. Changes in B- and T-lymphocyte and chemokine levels with rituximab treatment in multiple sclerosis. Arch Neurol. 2010;67(6):707–14.
60. Maurer MA, Tuller F, Gredler V, Berger T, Lutterotti A, Lunemann JD, et al. Rituximab induces clonal expansion of IgG memory B-cells in patients with inflammatory central nervous system demyelination. J Neuroimmunol. 2016;15(290):49–53.
61. Topping J, Dobson R, Lapin S, Maslyanskiy A, Kropshofer H, Leppert D, et al. The effects of intrathecal rituximab on biomarkers in multiple sclerosis. Mult Scler Relat Disord. 2016;6:49–53.
62. Komori M, Lin YC, Cortese I, Blake A, Ohayon J, Cherup J, et al. Insufficient disease inhibition by intrathecal rituximab in progressive multiple sclerosis. Ann Clin Transl Neurol. 2016;3(3):166–79.
63. Bergman J, Burman J, Gilthorpe JD, Zetterberg H, Jiltsova E, Bergenheim T, et al. Intrathecal treatment trial of rituximab in progressive MS: an open-label phase 1b study. Neurology. 2018;91(20):e1893–901.
64. Lovett-Racke AE, Gormley M, Liu Y, Yang Y, Graham C, Wray S, et al. B cell depletion with ublituximab reshapes the T cell profile in multiple sclerosis patients. J Neuroimmunol. 2019;15(332):187–97.
65. Gingele S, Jacobus TL, Konen FF, Hummert MW, Suhs KW, Schwenkenbecher P, et al. Ocrelizumab depletes CD20(+) T cells in multiple sclerosis patients. Cells. 2018;8(1).
66. Dunn N, Juto A, Ryner M, Manouchehrinia A, Piccoli L, Fink K, et al. Rituximab in multiple sclerosis: frequency and clinical relevance of anti-drug antibodies. Mult Scler. 2018;24(9):1224–33.
67. Bar-Or A, Calabresi PA, Arnlod D, Markowitz C, Shafer S, Kasper LH, et al. Rituximab in relapsing-remitting multiple sclerosis: a 72-week, open-label, phase I trial. Ann Neurol. 2008;63(3):395–400.
68. Naismith RT, Piccio L, Lyons JA, Lauber J, Tutlam NT, Parks BJ, et al. Rituximab add-on therapy for breakthrough relapsing multiple sclerosis: a 52-week phase II trial. Neurology. 2010;74(23):1860–7.
69. Castillo-Trivino T, Braithwaite D, Bacchetti P, Waubant E. Rituximab in relapsing and progressive forms of multiple sclerosis: a systematic review. PLoS One. 2013;8(7):e66308.
70. Alping P, Frisell T, Novakova L, Islam-Jakobsson P, Salzer J, Bjorck A, et al. Rituximab versus fingolimod after natalizumab in multiple sclerosis patients. Ann Neurol. 2016;79(6):950–8.
71. de Flon P, Gunnarsson M, Laurell K, Soderstrom L, Birgander R, Lindqvist T, et al. Reduced inflammation in relapsing-remitting multiple sclerosis after therapy switch to rituximab. Neurology. 2016;87(2):141–7.
72. Salzer J, Svenningsson R, Alping P, Novakova L, Bjorck A, Fink K, et al. Rituximab in multiple sclerosis: a retrospective observational study on safety and efficacy. Neurology. 2016;87(20):2074–81.
73. Granqvist M, Boremalm M, Poorghobad A, Svenningsson A, Salzer J, Frisell T, et al. Comparative effectiveness of rituximab and other initial treatment choices for multiple sclerosis. JAMA Neurol. 2018;75(3):320–7.
74. Kappos L, Li. D, Calabresi PA. Long-term safety and efficacy of ocrelizumab in patients with relapsing-remitting multiple sclerosis: week 144 results of a phase II, randomised, multicentre trial. 28th Congress of the European Committee for Treatment and Research in Multiple Sclerosis, Oct 10–13, 2012, Lyon, France.
75. Havrdova E, Arnold DL, Bar-Or A, Comi G, Hartung HP, Kappos L, et al. No evidence of disease activity (NEDA) analysis by epochs in patients with relapsing multiple sclerosis treated with ocrelizumab vs interferon beta-1a. Mult Scler J Exp Transl Clin. 2018;4(1):2055217318760642.

76. Frau J, Coghe G, Lorefice L, Fenu G, Cocco E. New horizons for multiple sclerosis therapeutics: milestones in the development of ocrelizumab. Neuropsychiatr Dis Treat. 2018;14:1093–9.
77. Hauser SL, Bar-Or A, Cohen J, Comi G, Correale J, Coyle PK, et al. Efficacy and safety of ofatumumab versus teriflunomide in relapsing multiple sclerosis: results of the phase 3 ASCLEPIOS I and II trials. Mult Scler. 2019;25(S2):890–938.
78. Fox EL-R, Wray S, Racke MK, Shubin R, Twyman C, Eubanks J, Su W. 6 Month results of a phase 2a multicenter study of ublituximab, a novel glycoengineered anti-CD20 monoclonal antibody, in relapsing multiple sclerosis. Mult Scler. 2018;24(S1):11–117.
79. Fox E. Final results of a placebo controlled, Phase 2 multicenter study of ublituximab (UTX), a novel glycoengineered anti-CD20 monoclonal antibody (mAb), in patients with relapsing forms of multiple sclerosis (RMS). Mult Scler. 2018;24(S2):8–120.
80. Fox E, Wray S, Shubin R, Lovett-Racke A, Huang D, Bass A, et al. Long-term follow-up results from the phase 2 multicenter study of ublituximab (UTX), a novel glycoengineered anti-CD20 monoclonal antibody (mAb), in patients with relapsing multiple sclerosis (RMS). Mult Scler. 2019;25(S2):357–580.
81. Steinman L, Fox E, Hartung H, Alvarez E, Qian P, Wray S, et al. Study design and patient demographics of the ULTIMATE phase III trials evaluating Ublituximab (UTX), a novel glycoengineered anti-CD20 monoclonal antibody (mAb), in patients with relapsing multiple sclerosis (RMS). Mult Scler. 2019;25(S2):523.
82. Theil D, Smith P, Huck C, Gilbart Y, Kakarieka A, Leppert D, et al. Imaging mass cytometry and single-cell genomics reveal differential depletion and repletion of B-cell populations following ofatumumab treatment in cynomolgus monkeys. Front Immunol. 2019;10:1340.
83. Memon AB, Javed A, Caon C, Srivastawa S, Bao F, Bernitsas E, et al. Long-term safety of rituximab induced peripheral B-cell depletion in autoimmune neurological diseases. PLoS One. 2018;13(1):e0190425.
84. Tallantyre EC, Whittam DH, Jolles S, Paling D, Constantinescu C, Robertson NP, et al. Secondary antibody deficiency: a complication of anti-CD20 therapy for neuroinflammation. J Neurol. 2018;265(5):1115–22.
85. Ocrelizumab and PML. Genentech; 2019. https://www.ocrelizumabinfo.com/content/dam/gene/ocrelizumabinfo/pdfs/progressive-multifocal-leukoencephalopathy.pdf.